

Hyoid bone

It is stored in the neck muscles between the floor of the mouth and the larynx. It consists of a **body** and a **horns**. It is tangible.

- **Corpus ossis hyoidei**

Unpaired lingual body - is placed transversely in front.

- **Cornua majora**

Paired formations in the continuation of the body towards the back. They form a U-shape with the body.

- **Cornua minora'**

Short conical formations movably connected cartilage to the lateral margin of the body.

- **Ligamentum stylohyoideum'**

It connects the small horns with the processus styloideus. Bony formations can sometimes occur in this ligament.

Links

Related Articles

- Splanchnocranium bones

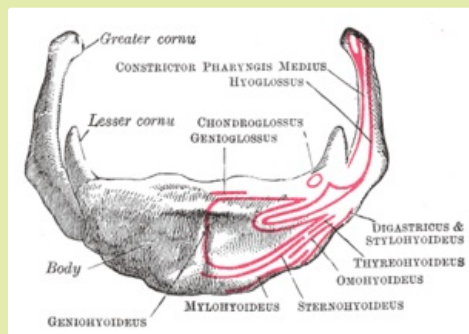
References

- ČIHÁK, Radomír – GRIM, Miloš. *Anatomie*. 2., uprav. a dopl edition. Grada Publishing, 2002. 470 pp. vol. 2. ISBN 80-7169-970-5.

Template:Navbox - bones

Kategorie:Anatomy

[[Soubor:|225px|alt=]]



A02.1.16.001 (<http://www.unifr.ch/ifaa/Public/EntryPage/TA98%20Tree/Entity%20TA98%20EN/02.1.16.001%20Entity%20TA98%20EN.htm>)

hinge of the larynx