

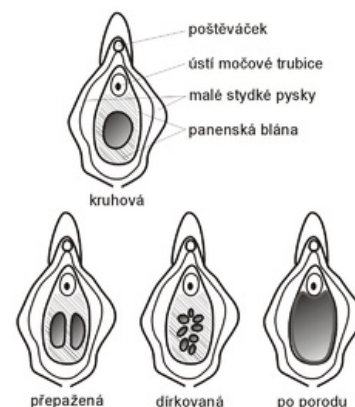
Hymen

Virgin membrane (hymen) is a mucosal duplication in *ostium vaginae*. The name originated from the Greek word *hymēn*, which means membrane. The composition and shape of hymens are strongly dependent on estrogens, as well as the vaginal mucosa. However, we can observe this on the hymen with the naked eye - that's why the hymen is figuratively called the "mirror of estrogens".

Types of hymens

We distinguish the following types of hymens:

- *hymen anularis* – basic shape of hymen, annular membrane with opening of varying size;
- *hymen fimbriatus* – is a thickened type of hymen, which is caused by the excessive action of estrogens;
- *hymen semilunaris* – a type of hymen resembling in appearance the semilunar valves of vessels;
- *hymen semilunaris fimbriatus* – altered by estrogenization *hymen semilunaris*, sometimes it can even partially cover the entrance to the urethra;
- *hymen binocularis seu septus* – it has two openings between which there is a fibrous partition of varying thickness;
- *hymen cruciatus*, *hymen cribriformis* – less common species, they can change estrogenically too.



Types of hymens – circular (*h. anularis*), partitioned (*h. semilunaris*), perforated (*h. cribriformis*), after a birth

Embryonal origin

The cavity of the vagina remains separated from *sinus urogenitalis* by a thin plate of tissue – hymen. The hymen consists of mesenchyme covered by epithelium *sinus urogenitalis* and epithelium of vagina. Prenatally, a small opening is formed in it *ostium vaginae*.

Defloration

Defloration is the process of rupture of the hymen, which occurs during invasive penetration into this area. Because the hymen is richly supplied with nerve endings, defloration is usually very painful. In a sexually active woman, the hymen is torn in many places, so that only a few of it remains *carunculae hymenales*. **After birth, only carunculae myrtiformes will remain of it. Defloration does not necessarily occur only during coitus. It can also occur, for example, during a gynecological examination, masturbation or inserting a tampon. Recently, a trend has come from the West to surgically restore the integrity of the membrane.**

Links

Related articles

- Vagina
- Estrogens

Reference

- ROB, L. *Gyneekologie : Druhé, doplněné a přepracované vydání*. 2. edition. Galén, 2008. ISBN 978-80-7262-501-7.
- SADLER, T.W.. *Langmanova lékařská embryologie*. 1 (překlad 10. vydání) edition. Grada, 2011. ISBN 978-80-247-2640-3.
- ČIHÁK, R. . *Anatomie 1*. 3. edition. Grada, 2011. ISBN 978-80-247-3817-8.