

Histology MCQs/Respiratory System

1 How is arranged muscle tissue in the wall of bronchi?

- ☐ Longitudinal bundles of smooth muscle cells
- ☐ Longitudinal bundles of striated muscle fibers
- ☐ Spiral bundles of smooth muscle cells
- ☐ Spiral bundles of striated muscle fibers

2 What is main function of **type II pneumocyte**?

- ☐ It is a part of neuroendocrine system
- ☐ It is a site of diffusion of gases
- ☐ It produces a surfactant
- ☐ It produces a mucus

3 Which type of muscle tissue is made **trachealis muscle**?

- ☐ Myoepithelium
- ☐ Smooth muscle
- ☐ Striated muscle
- ☐ Mixture of smooth and striated muscle

4 Which type of glands sits in lamina propria mucosae of the trachea?

- ☐ Serous
- ☐ Mucinous
- ☐ Seromucinous
- ☐ There are no glands there

5 Which type of cartilage forms the cartilaginous skeleton of the nose?

- ☐ Hyaline cartilage
- ☐ Elastic cartilage
- ☐ Main part of cartilages is composed of hyaline cartilage, but some cartilages are elastic
- ☐ Main part of cartilages is composed of elastic cartilage, but some cartilages are hyaline

6 Which epithelium covert main part of the **vocal fold** (true vocal fold)?

- ☐ Stratified squamous non-keratinizing
- ☐ Stratified squamous keratinizing
- ☐ Simple squamous non-keratinizing
- ☐ Simple squamous keratinizing

7 Which epithelium covers often at least a part of the **vestibular fold** (false vocal fold)?

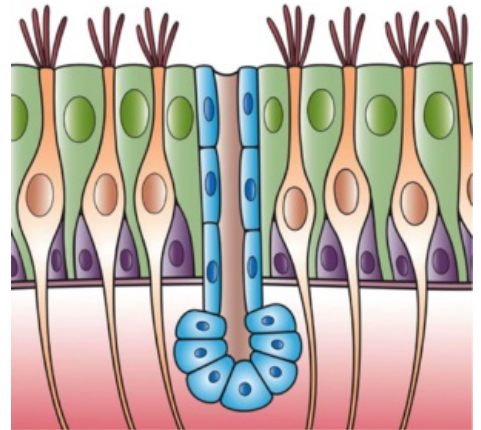
- ☐ Stratified squamous non-keratinizing
- ☐ Stratified squamous keratinizing
- ☐ Simple squamous non-keratinizing
- ☐ Simple squamous keratinizing

8 Which muscle tissue is a material of the **vocal muscle**?

- ☐ Smooth muscle
- ☐ Striated muscle
- ☐ Smooth muscle in the caudal part, striated muscle in the cranial part
- ☐ Smooth muscle in the cranial part, striated muscle in the caudal part

9 Which of following statements about **elastic fibers** in lungs is the most accurate?

- ☐ There are elastic fibers in the lung, but in the wall of arteries only
- ☐ There is plenty of elastic fibers in the lungs
- ☐ There are some elastic fibers in the lung



Epithelium of respiratory ways is composed of few distinct cell populations.

☐ There are no elastic fibers in the lung

10 Which type of tissue forms an inner "skeleton" of the epiglottis?

- ☐ Fibrocartilage
- ☐ Elastic cartilage
- ☐ Hyaline cartilage
- ☐ Dense connective tissue

11 Which of the following statements about **arteries in the lung circulation** is true?

- ☐ There is a low pressure in the pulmonary circulation, therefore arteries are thin-walled than arteries in the system circulation
- ☐ There is a low pressure in the pulmonary circulation, therefore arteries are thick-walled than arteries in the system circulation
- ☐ There is a high pressure in the pulmonary circulation, therefore arteries are thin-walled than arteries in the system circulation
- ☐ There is a high pressure in the pulmonary circulation, therefore arteries are thick-walled than arteries in the system circulation

Submit

Links

- List of all tests: Histology MCQs
- Portal: Histology