

# Hibernoma



**Hibernoma** is a tumor of brown adipose tissue. It consists of multivacuolar adipocytes (vacuoles do not compress and deform the nucleus) with a large number of mitochondria (microscopically eosinophilic, macroscopically brown). It occurs mainly in the subcutaneous tissue of the interscapular region of newborns.

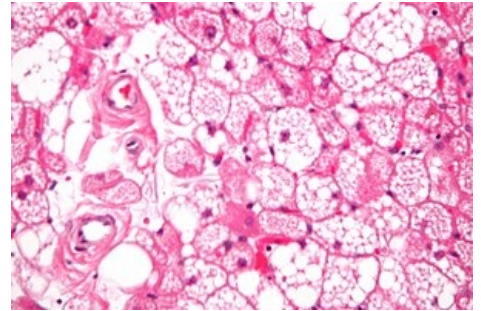
## Links

### Related articles

- Lipoma
- Liposarcoma
- Lipoblastoma

### Source

- PASTOR, Jan. *Langenbeck's medical web page: Nádory* [online]. ©2006. [cit. 2010-04-18]. <<http://www.freewebs.com/langenbeck/Nadory.rar>>.



Hibernoma