

Glomerulonephritis

Glomerulonephritis^[1] belongs to glomerulopathies. It is a disease of the glomeruli, which has an inflammatory nature and is conditioned by immunological processes. Glomerulonephritis can be divided into **primary** (where only the kidneys are affected) and **secondary**, when kidney involvement is part of another systemic disease (for example, systemic lupus erythematosus).

Classification of glomerulonephritis

The classification of glomerulonephritis (GN) is complicated and not completely complete yet. There are several criteria according to which individual pathological units can be classified.

Division according to time perspective

1. Acute glomerulonephritis
2. Subacute glomerulonephritis
3. Chronic glomerulonephritis

Division according to etiology

1. Primary glomerulonephritis - or also idiopathic. We do not know the exact cause. The disease is only related to the kidneys.

- Acute poststreptococcal GN.
- FSGS.
- Syndrome of minimal changes (Minimal change disease).
- Membranoproliferative GN.
- IgA nephropathy.
- Membranous GN.

2. Secondary glomerulonephritis - a disease in which we know the triggering process, the kidneys are affected as part of another systemic disease.

- Diabetic nephropathy, Kidney amyloidosis.
- Systemic vasculitides with kidney involvement.
- Kidney involvement in other systemic diseases (SLE, Henoch-Schönlein purpura).
- Goodpasture syndrome.
- Light chain deposit disease (LCDD).

Division according to the nature of the manifestation in primary GN

1. Proliferative glomerulonephritis - characterized by clearly expressed inflammatory events. Clinical signs: more pronounced cell proliferation, with positive immunofluorescence, mixed findings in the urine. They are more often manifested by nephritic syndrome.

- Acute poststreptococcal glomerulonephritis.
- RPGN
- Mesangioproliferative glomerulonephritis (IgA nephropathy)
- Membranoproliferative glomerulonephritis.

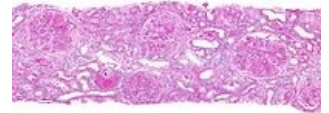
2. Nonproliferative glomerulonephritis - characterized by a low degree of inflammation. Clinical signs: without cell proliferation, with negative immunofluorescence, proteinuria in the urine. They are also most often manifested by nephrotic syndrome.

- Syndrome of minimal changes (Minimal change disease).
- FSGS - focal segmental glomerulosclerosis.
- Membranous nephropathy.

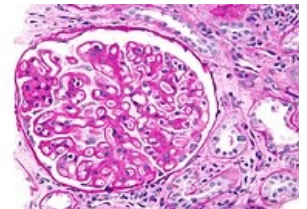
Rapidly progressive glomerulonephritis

This is a form of glomerulonephritis that causes deterioration of renal function over days or weeks. Histologically, it is a sickle-shaped form of GN, where the sickles affect at least 75% of the glomeruli. Most often, the following units take place under this image:

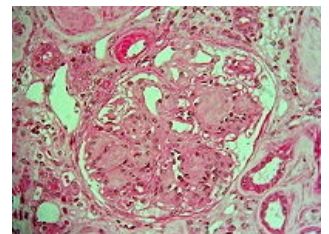
1. ANCA associated renal vasculitis - antibodies against neutrophil cytoplasm (Granulomatosis with polyangiitis, Microscopic polyangiitis, Churg-Strauss syndrome)



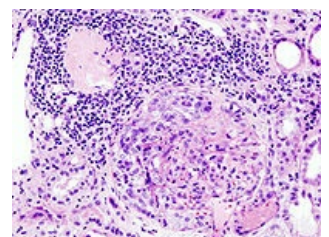
Membranoproliferative glomerulonephritis



Membranous nephropathy



Diabetic nephropathy



ANCA positive glomerulonephritis.

2. Anti-GBM antirenal glomerulonephritis - basement membrane antibodies (Goodpasture syndrome)
3. Immunocomplex glomerulonephritis - deposits of immune complexes (SLE, poststreptococcal glomerulonephritis, IgA nephropathy)

Links

Related Articles

- Acute glomerulonephritis • Rapidly progressive glomerulonephritis • Chronic glomerulonephritis
- Glomerulopathy: Glomerulopathy manifested by nephrotic syndrome
- Nephrotic syndrome • Nephrotic syndrome
- Acute glomerulonephritis/case report

External links

- TECHmED: Glomerulonephritis (<https://www.techmed.sk/glomerulonephritis/>) - Useful information about glomerulonephritis with pictures (Slovak)

Literature

- KUMAR, Vinay – ABBAS, Abul K – FAUSTO, Nelson. *Robbins basic pathology*. 8. edition. Philadelphia : Saunders/Elsevier, 2007. ISBN 978-1-4160-2973-1.
- CZECH, Richard. *Intern*. 1. edition. Prague : Triton, 2010. 855 pp. ISBN 978-80-7387-423-0.

References

1. KLENER, Paul. *Internal Medicine*. Third, revised and supplemented edition edition. Prague : Karolinum, Galen, 2006. 1158 pp. pp. 739–740. ISBN 80-7262-430-X.