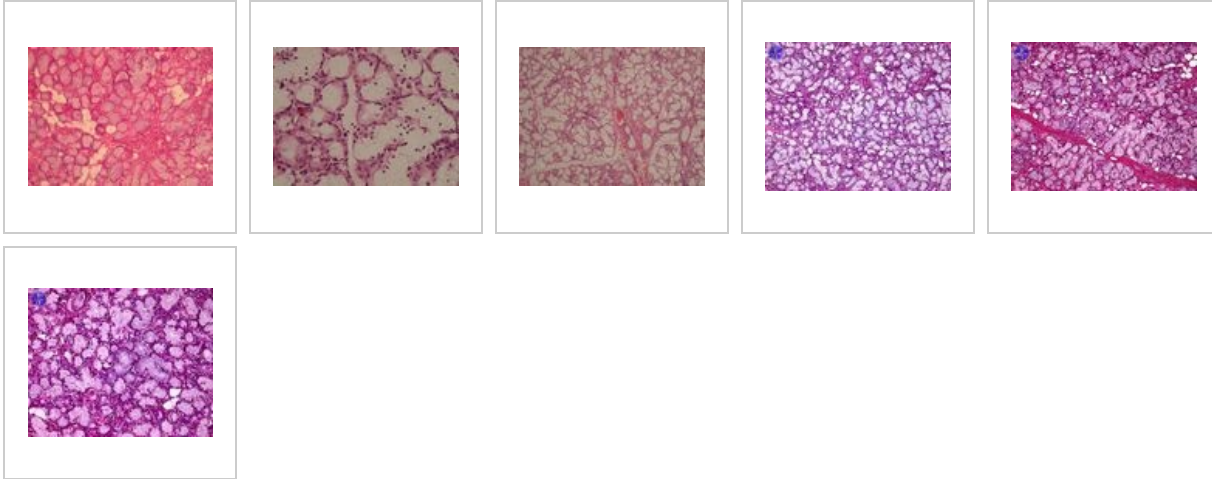


# Gl. sublingualis (SFLT)



## Gastrointestinal tract

- Dorsum of tongue (SFLT)
- Tongue - radix (SFLT)
- Tongue - tonsilla lingualis (SFLT)
- Gl. submandibularis (SFLT)
- Gl. parotis (SFLT)
- Gl. sublingualis (SFLT)
- Esophagus (SFLT)
- Gaster - cardia (SFLT)
- Gaster - fundus (SFLT)
- Pylorus - duodenum (SFLT)
- Duodenum (SFLT)
- Small intestine (SFLT)
- Colon (SFLT)
- Appendix (SFLT)
- Liver (SFLT)
- Gallbladder (SFLT)
- Pancreas (SFLT)

## Links

- Histology Atlas (3rd faculty)