

Galea aponeurotica



It is a large tendon on the calf of the skull, into which the muscles of the cranial vault (m. epicranius), i.e. m. occipitalis, m. frontalis and m. temporoparietalis, are attached. It is firmly attached to the skin, but the connection with the periosteum of the skull is weak, so it can be easily torn away from the periosteum.

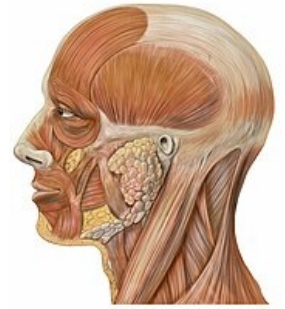
Links

Related articles

- Caput succedaneum
- Muscles of the cranial vault

References

- ČIHÁK, Radomír – GRIM, Miloš. *Anatomie*. 2., uprav. a dopl edition. Praha : Grada Publishing, 2002. 470 pp. vol. 2. ISBN 80-7169-970-5.



Galea aponeurotica and the muscles that attach to it.