

Fracture healing disorders

Fracture healing disorders include :

- prolonged healing;
- malunion;
- hinge.

Prolonged fracture healing

The term *prolonged fracture healing* means that the healing time is longer than the expected fracture healing (6-8 weeks).

It is in process:

- by prolonging immobilization ;
- in conservatively treated fractures with operative osteosynthesis ;
- sometimes spongioplasty is also performed.

Malunion

Malunion represents healing in a malposition.

- It can be *asymptomatic* or manifest as *dysfunction* ;
- arises during imperfect reposition or after unstable fixation (*redislocation* - therefore repeated X-ray checks are necessary);
- osteotomy and osteosynthesis are performed in the correct position to prevent arthrosis from improper loading.

Paklub

A knock-on (*pseudarthrosis*) is characterized as a disorder of fracture healing, when bone fragments do not fuse together even in a time twice as long as the normal course of healing (until then, we are only talking about *prolonged healing*).

The fracture line is filled with fiber and surrounded by a fibrous sheath that contains fluid.

Classification according to clinical findings

- **weak** : unstable, with great pathological *mobility*, cannot bear loads
- **solid** : without pathological momentum, withstands loads

Classification according to Čech and Weber

1. **Vital** – insufficient stabilization and immobilization of the fracture, **sufficient blood supply** and tendency to healing..
 - *Hypertrophic* ;
 - *normotrophic* – occurs mostly in unstable osteosyntheses;
 - *oligotrophic* – usually arises from overextended skeletal traction.
2. **Vital - insufficient blood supply**, sclerotization or osteoporosis of bone ends.
 - *Dystrophic* ;
 - *necrotic* ;
 - *defective* ;
 - *atrophic*.

The most serious form is an infected joint - it occurs in all the above-mentioned forms and can lead to limb amputation. A special example is the tibial joint in fractures of the lower leg, where the fibula heals earlier and acts as a spacer (similarly, earlier healing of the ulna acts in fractures of the radius).

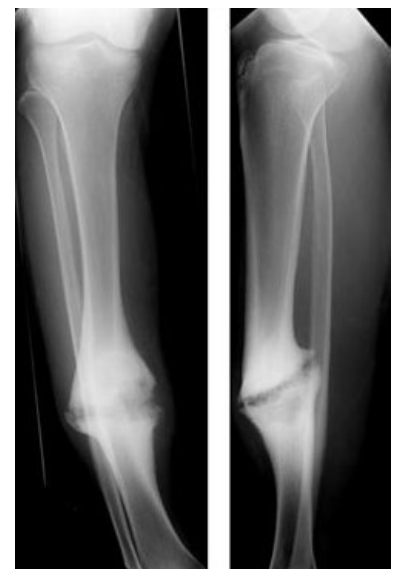Links

related articles

- Bone
- Prolonged fracture healing



poorly healed fracture of the femur



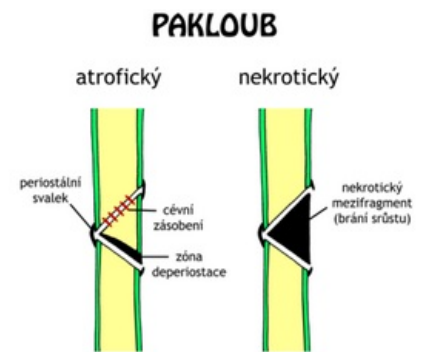
Hypertrophic tibial arch

- Bone growth and healing

Source

- PASTOR, Jan. *Langenbeck's medical web page* [online]. [cit. 12.4.2010]. <<https://langenbeck.webs.com/>>.

-
-
-
-



Atrophic and necrotic joint