

Formations behind the medial ankle

The space behind the medial ankle (often referred to as the canalis malleolaris or tarsal canal) is bounded by **the retinaculum musculorum flexorum** (medially), **the malleolus medialis** (ventrally) and **the tuber calcanei** (dorsally).

The tibialis posterior **tendon** , the flexor digitorum longus **tendon** , **the tibialis posterior artery** together with **the tibialis posterior vein**, the tibialis n. and the flexor hallucis longus **tendon** pass here, which is the only tendon that does not rest on the ankle and passes through the processus posterior tali.

Mnemonics are used for easy remembering:

TIDIAVENEH - tendon of **TI** bialis posterior muscle, tendon of flexor muscle **DI** gitorum longus, **A** rteria et **VE** na tibialis posterior, **NE** rvus tibialis and tendon of flexor **H** allucis longus

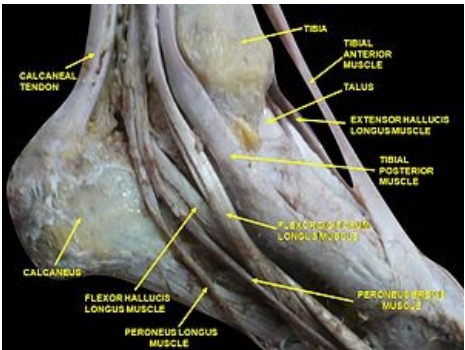
TIDIVANHA - tendon of **TI** bialis posterior muscle, tendon of flexor **DI** gitorum longus, **V**. tibialis posterior, **A**. tibialis posterior, **N**. tibialis, m. flexor **HA** llucis longus

Related articles

- Anatomy mnemonics
- Formations in front of the medial ankle
- Formations behind the lateral ankle

References

- CIHÁK, Radomír. *Anatomy 1* . 2nd edition. Prague: Grada Publishing, a.s., 2008. 516 pp. ISBN 80-7169-970-5.
- GRIM, Miloš and Rastislav DRUGA, et al. *Fundamentals of anatomy, 5. Anatomy of body regions* . 1st edition. Prague: Galén, 2008. 119 pp. ISBN 978-80-7262-179-8.



Malleolar canal tarsal canal

Malleolar canal	
Limitation in the media	flexor muscles
Bordered dorsally	tuber calcanei
Bordered ventrally	medial malleolus
Contents	m. tibialis posterior , m. flexor digitorum longus , a. tibialis posterior, v. tibialis posterior, n. Tibialis , m. flexor hallucis longus
aid	TiDiAVeNeH