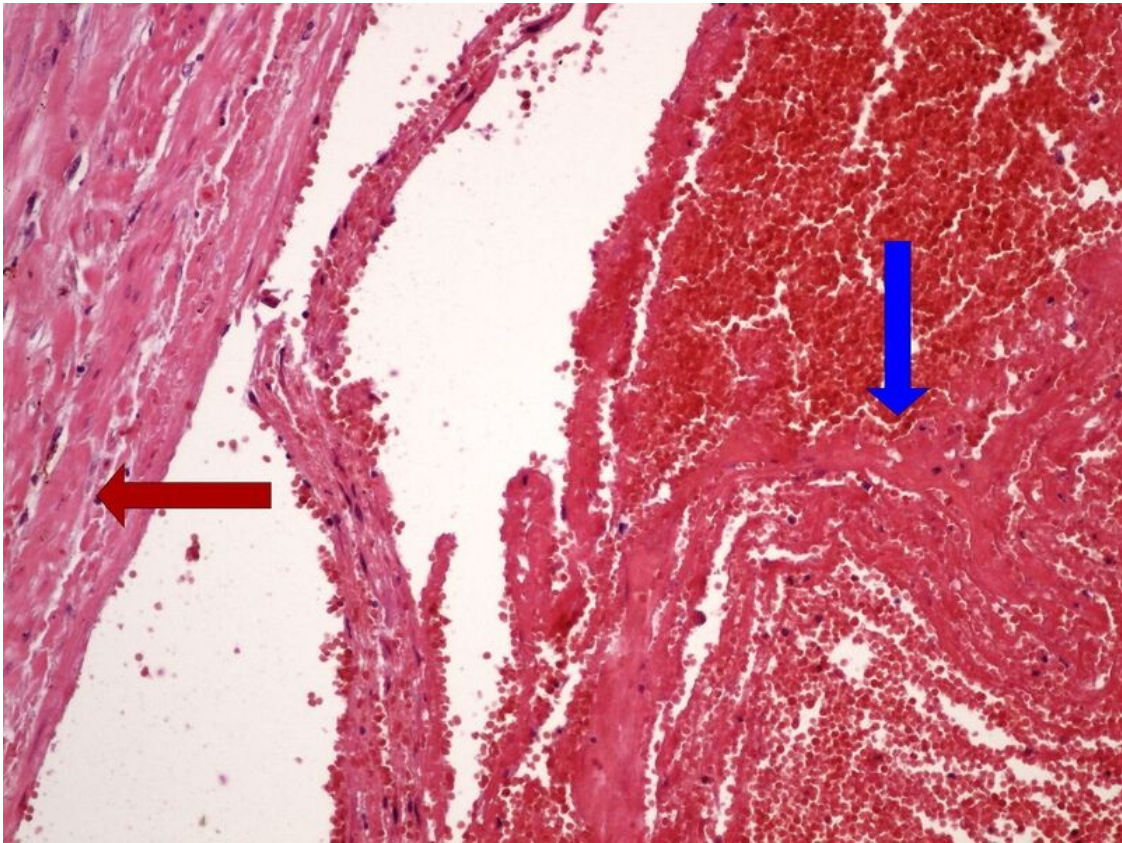


File:Z5-4 acute thrombosis 20x .jpg



Size of this preview: 800 × 600 pixels.

Original file (1,280 × 960 pixels, file size: 276 KB, MIME type: image/jpeg)

 **Open in Media Viewer** 

Summary

Description
acute thrombosis

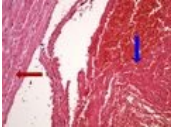
Author
Patologie3LF

Source
https://www.wikiskripta.eu/index.php?curid=48307#/media/Soubor:Z5-4_acute_thrombosis_cerstva_tromboza_20x_oznaceno.jpg

Date
2023-05-30

File history

Click on a date/time to view the file as it appeared at that time.

	Date/Time	Thumbnail	Dimensions	User	Comment
current	14:16, 30 May 2023		1,280 × 960 (276 KB)	Vali.kolarova (talk contribs)	{ {File description = acute thrombosis author = Patologie3LF source = https://www.wikiskripta.eu/index.php?curid=48307#/media/Soubor:Z5-4_acute_thrombosis_cerstva_tromboza_20x_oznaceno.jpg date = 2023-05-30 } }

You cannot overwrite this file.

File usage

The following page uses this file:

- Module GFPP - Practice no. 5

Metadata

This file contains additional information, probably added from the digital camera or scanner used to create or digitize it.

If the file has been modified from its original state, some details may not fully reflect the modified file.