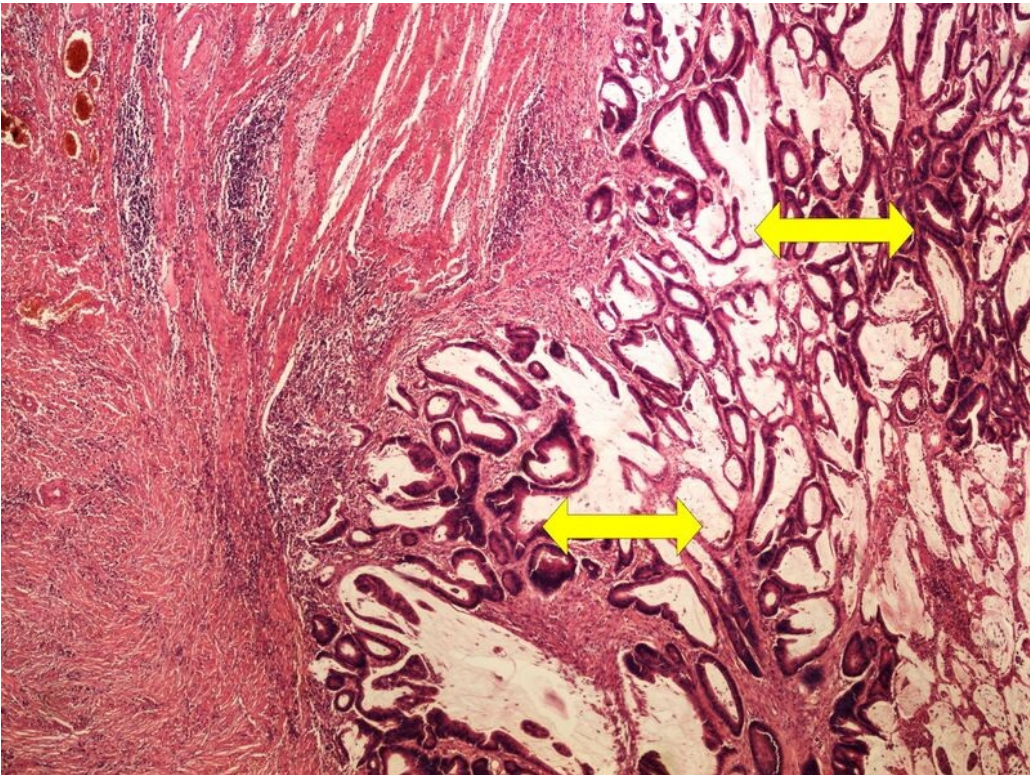


File:Z10-13 tubular adenocarcinoma 4x.jpg



Size of this preview: 800 × 600 pixels.

Original file (1,280 × 960 pixels, file size: 450 KB, MIME type: image/jpeg)

[Open in Media Viewer](#)

Summary

Description

tubular adenocarcinoma

Author

Patologie3LF

Source

https://www.wikiskripta.eu/index.php?curid=48313#/media/Soubor:Z10-13_tubular_adenocarcinoma_tubularni_adenokarcinom_4x_oznaceno.jpg

Date

2023-05-29

File history

Click on a date/time to view the file as it appeared at that time.

	Date/Time	Thumbnail	Dimensions	User	Comment
current	20:27, 29 May 2023		1,280 × 960 (450 KB)	Vali.kolarova (talk contribs)	{{File description = tubular adenocarcinoma author = Patologie3LF source = https://www.wikiskripta.eu/index.php?curid=48313#/media/Soubor:Z10-13_tubular_adenocarcinoma_tubularni_adenokarcinom_4x_oznaceno.jpg date = 2023-05-29 }}

You cannot overwrite this file.

File usage

The following page uses this file:

- Module GFPP - Practice no. 11

Metadata

This file contains additional information, probably added from the digital camera or scanner used to create or digitize it.

If the file has been modified from its original state, some details may not fully reflect the modified file.