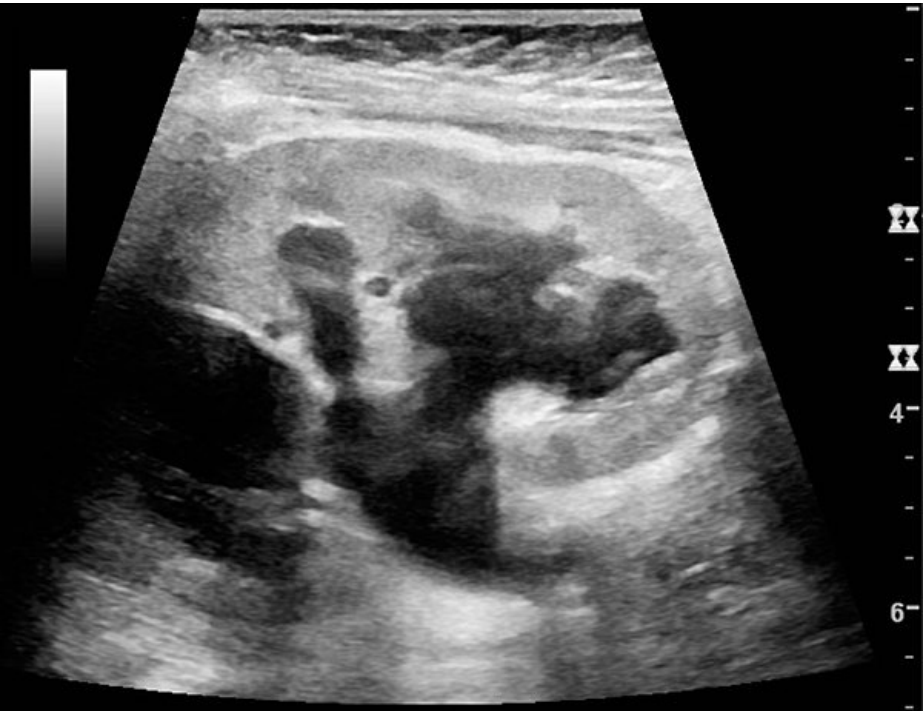

File:Ultrasonography of hydronephrosis due to ureteropelvic junction obstruction.jpg



No higher resolution available.


Ultrasonography_of_hydronephrosis_due_to_ureteropelvic_junction_obstruction.jpg (600 × 460 pixels, file size: 48 KB, MIME type: image/jpeg)

 [Open in Media Viewer](#) 

Sonographic image of dilatation of the calicopelvic system of the kidney

File history

Click on a date/time to view the file as it appeared at that time.

	Date/Time	Thumbnail	Dimensions	User	Comment
current	23:16, 20 May 2023		600 × 460 (48 KB)	Soniaamis (talk contribs)	

You cannot overwrite this file.

File usage

The following page uses this file:

- Retroperitoneal fibrosis