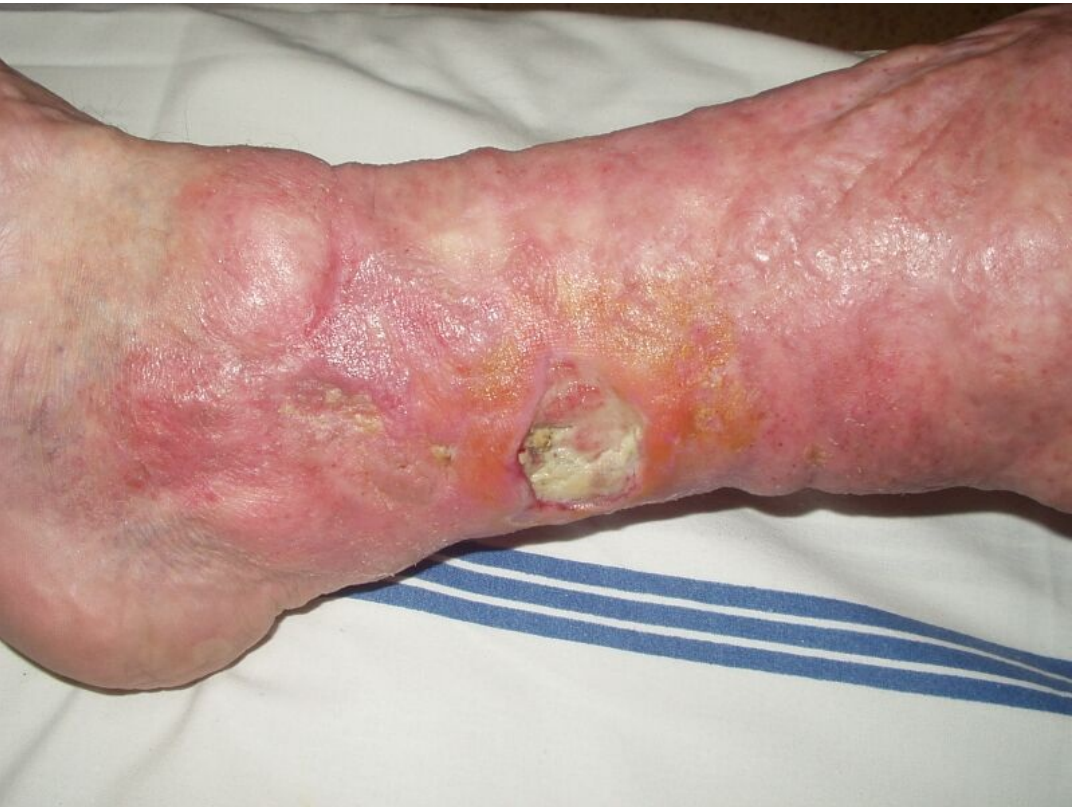

File:Trophic defect.jpg



Size of this preview: 800 × 600 pixels.

Original file (1,600 × 1,200 pixels, file size: 410 KB, MIME type: image/jpeg)

 [Open in Media Viewer](#) 

Summary

Description
Chronic trophic defect repeatedly occurs several years after avulsion in the lower limb.


Author
MUDr. Josef Bláha

Source
https://www.wikiskripta.eu/w/Soubor:Trof_defekt_hlub_popal.jpg

Date
16.12.2022

File history

Click on a date/time to view the file as it appeared at that time.

	Date/Time	Thumbnail	Dimensions	User	Comment
current	20:11, 16 December 2022		1,600 × 1,200 (410 KB)	Terezaj (talk contribs)	{ {File description = Chronic trophic defect repeatedly occurs several years after avulsion in the lower limb. author = MUDr. Josef Bláha source = https://www.wikiskripta.eu/w/Soubor:Trof_defekt_hlub_popal.jpg date = 16.12.2022 } }

You cannot overwrite this file.

File usage

The following page uses this file:

- Fascial excision

Metadata

This file contains additional information, probably added from the digital camera or scanner used to create or digitize it.
If the file has been modified from its original state, some details may not fully reflect the modified file.

Image title	OLYMPUS DIGITAL CAMERA
Camera manufacturer	OLYMPUS OPTICAL CO.,LTD

Camera model	C2Z,D520Z,C220Z
Exposure time	1/30 sec (0.033333333333333)
F Number	f/8
ISO speed rating	80
Date and time of data generation	Unknown date
Lens focal length	5 mm