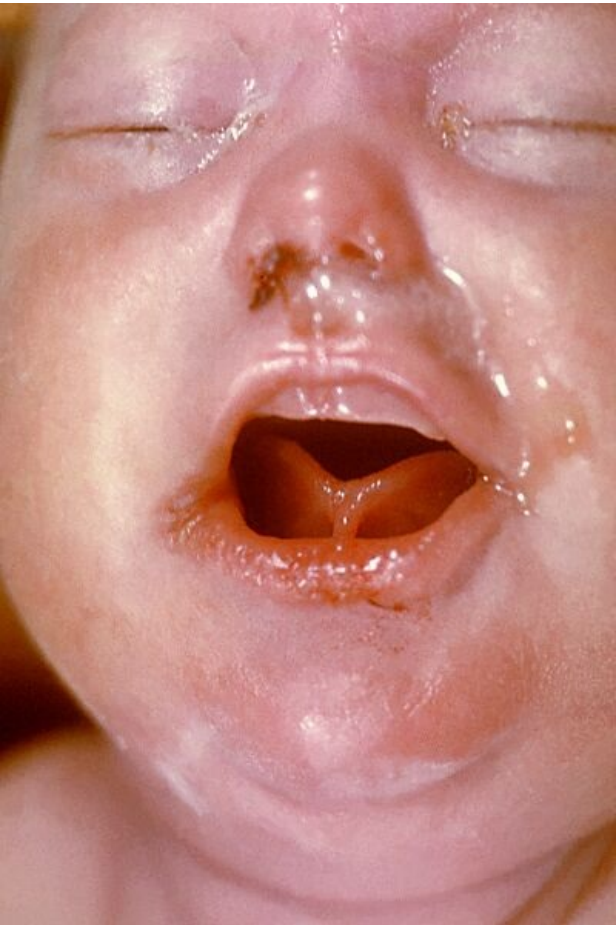

# File:The face of a newborn infant with Congenital Syphilis.tif.jpg




Size of this preview: 400 × 600 pixels.

Original file (800 × 1,200 pixels, file size: 239 KB, MIME type: image/jpeg)

The face of a newborn infant with Congenital Syphilis

## File history

Click on a date/time to view the file as it appeared at that time.

	Date/Time	Thumbnail	Dimensions	User	Comment
current	00:22, 22 January 2022		800 × 1,200 (239 KB)	Hnilicovaeva (talk   contribs)	

You cannot overwrite this file.

## File usage

The following page uses this file:

- Congenital syphilis

## Metadata

This file contains additional information, probably added from the digital camera or scanner used to create or digitize it.

If the file has been modified from its original state, some details may not fully reflect the modified file.

Image title	04/63 Dr. Norman Cole The face of a newborn infant displaying pathologic morphology indicative of congenital syphilis. A pregnant woman with syphilis can pass <i>T. pallidum</i> to her unborn child, who may be born with serious mental and physical problems as a result of this infection. When a newborn is affected it is known as “Congenital Syphilis”.
----------------	--