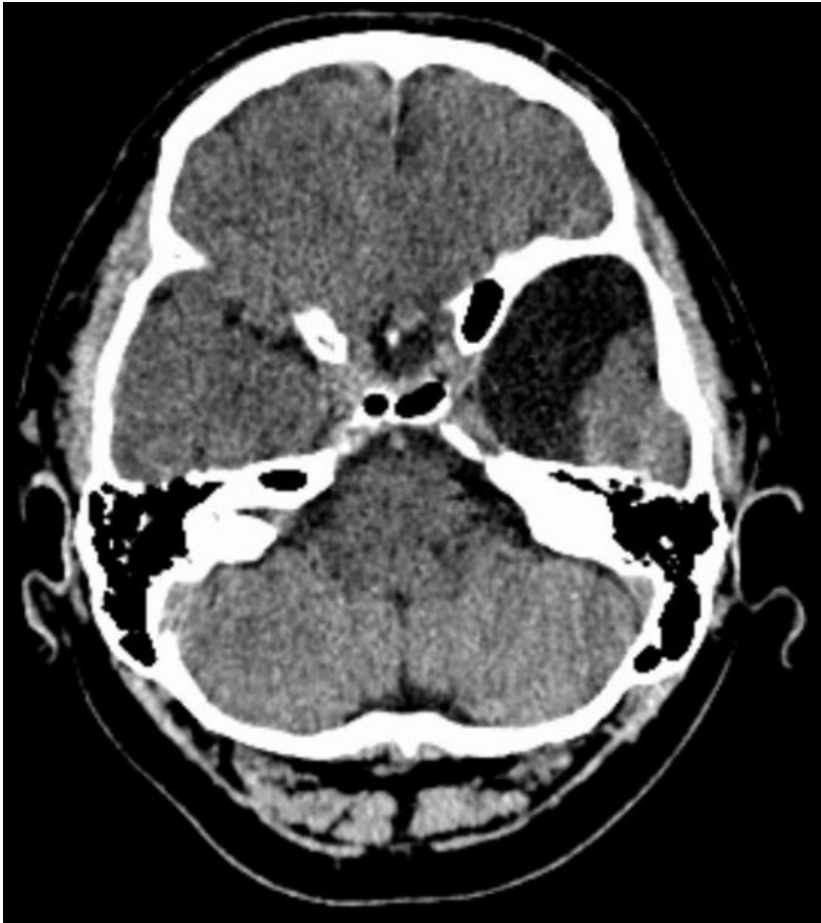


# File:Temporale Arachnoidalzyste links CT axial.jpg




Size of this preview: 533 × 599 pixels.

Original file (800 × 899 pixels, file size: 89 KB, MIME type: image/jpeg)

Transverse plane

## File history

Click on a date/time to view the file as it appeared at that time.

	Date/Time	Thumbnail	Dimensions	User	Comment
current	12:59, 9 May 2022		800 × 899 (89 KB)	Tereza Bergendyová (talk   contribs)	

You cannot overwrite this file.

## File usage

The following 2 pages use this file:

- Arachnoid cysts
- Congenital defects of the nervous system