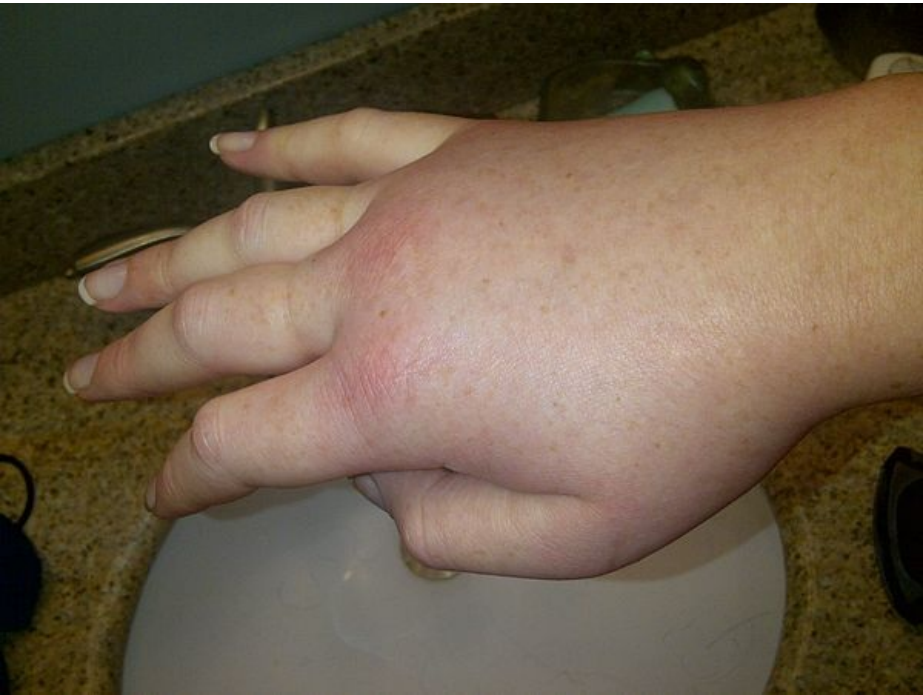

File:Swollen hand during a hereditary angioedema attack..jpg



No higher resolution available.


Swollen_hand_during_a_hereditary_angioedema_attack..jpg (600 × 450 pixels, file size: 34 KB, MIME type: image/jpeg)

 [Open in Media Viewer](#) 

pic

File history

Click on a date/time to view the file as it appeared at that time.

	Date/Time	Thumbnail	Dimensions	User	Comment
current	00:44, 21 May 2023		600 × 450 (34 KB)	Soniaamis (talk contribs)	

You cannot overwrite this file.

File usage

The following 2 pages use this file:

- Hereditary Angioedema
- Hereditary angioedema

Metadata

This file contains additional information, probably added from the digital camera or scanner used to create or digitize it.

If the file has been modified from its original state, some details may not fully reflect the modified file.