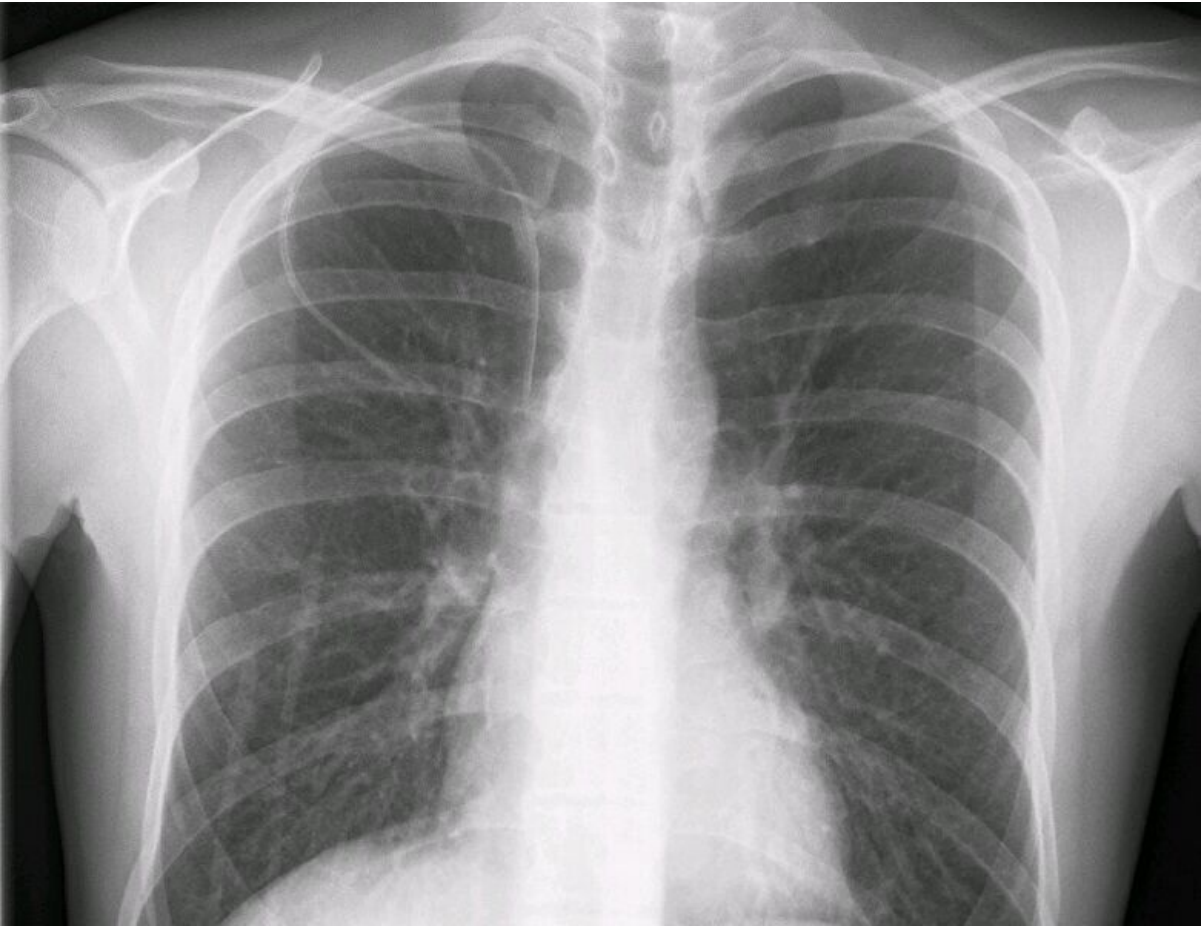


File:Subclavian central veinous catheter xray.jpg




Size of this preview: 781 × 600 pixels.

Original file (784 × 602 pixels, file size: 68 KB, MIME type: image/jpeg)

Giant. 3: Skiagraphic control of catheter insertion into the subclavian vein

File history

Click on a date/time to view the file as it appeared at that time.

| | Date/Time | Thumbnail | Dimensions | User | Comment |
|---------|------------------------|---|-------------------|-------------------------------|---------|
| current | 22:53, 6 November 2022 |  | 784 × 602 (68 KB) | JuneScndler (talk contribs) | |

You cannot overwrite this file.

File usage

The following page uses this file:

- Central venous access

Metadata

This file contains additional information, probably added from the digital camera or scanner used to create or digitize it.

If the file has been modified from its original state, some details may not fully reflect the modified file.