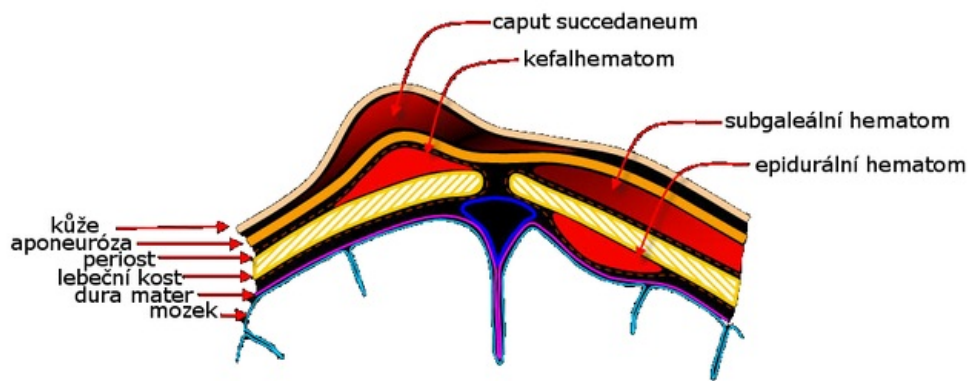


File:Scalp hematomas cesky.png



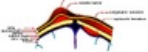
Size of this preview: 800 × 313 pixels.
Original file (1,059 × 414 pixels, file size: 137 KB, MIME type: image/png)

Summary

Description
Write a description here
Author
Author's name and surname
Source
Source web address or "own work"
Date
Date

File history

Click on a date/time to view the file as it appeared at that time.

	Date/Time	Thumbnail	Dimensions	User	Comment
current	19:09, 1 February 2023		1,059 × 414 (137 KB)	Marka (talk contribs)	{{File description = Write a description here author = Author's name and surname source = Source web address or "own work" date = Date }}

You cannot overwrite this file.

File usage

The following 5 pages use this file:

- Birth Trauma
- Birth traumatism
- Caput succedaneum
- Cephalhematoma
- Kefalhematoma

Metadata

This file contains additional information, probably added from the digital camera or scanner used to create or digitize it.
If the file has been modified from its original state, some details may not fully reflect the modified file.