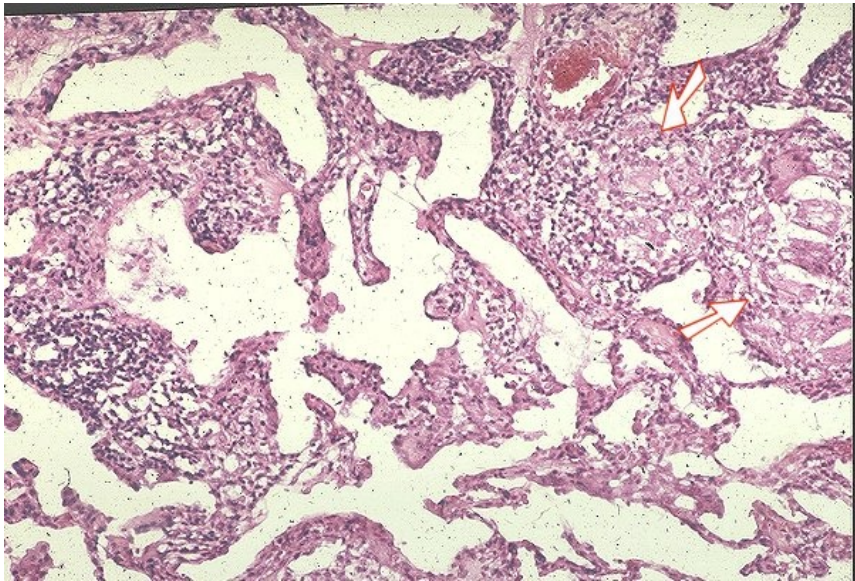


File:Sarkoidóza - vývoj granulomu 010.jpeg



No higher resolution available.

Sarkoidóza - vývoj granulomu 010.jpeg (600 × 406 pixels, file size: 125 KB, MIME type: image/jpeg)

Summary

Description

11. Non-granulomatous interstitial pneumonia/alveolitis. Arrows point to formed granulomas.

Author

Yale Rosen, M.D.

Source

<http://granuloma.homestead.com/Development.html>

Date

2012-05-18

File history

Click on a date/time to view the file as it appeared at that time.

	Date/Time	Thumbnail	Dimensions	User	Comment
current	21:01, 12 May 2023		600 × 406 (125 KB)	Annavotrubova (talk contribs)	{{File description = 11. Non-granulomatous interstitial pneumonia/alveolitis. Arrows point to formed granulomas. author = Yale Rosen, M.D. source = http://granuloma.homestead.com/Development.html date = 2012-05-18 }}

You cannot overwrite this file.

File usage

The following page uses this file:

- Sarcoidosis (pathology)