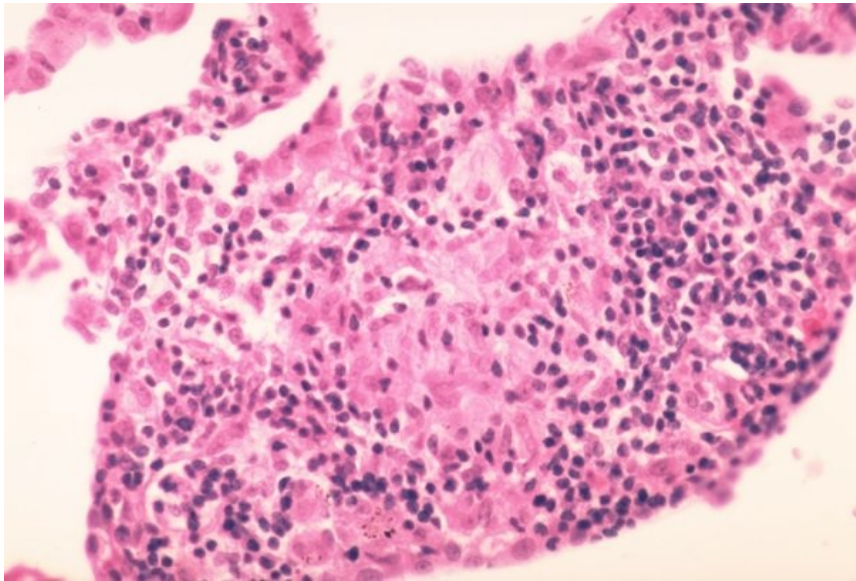


# File:Sarkoidóza - vývoj granulomu 007.jpeg



No higher resolution available.

Sarkoidóza\_-\_vývoj\_granulomu\_007.jpeg (600 × 406 pixels, file size: 62 KB, MIME type: image/jpeg)

## Summary

### Description

8. Non-granulomatous interstitial pneumonia/alveolitis. Late phase of granuloma formation. The lesion becomes more compact and better defined.

### Author

Yale Rosen, M.D.

### Source

<http://granuloma.homestead.com/Development.html>

### Date

2012-05-18

## File history

Click on a date/time to view the file as it appeared at that time.

	Date/Time	Thumbnail	Dimensions	User	Comment
current	<b>19:55, 12 May 2023</b>		600 × 406 (62 KB)	Annavotrubova (talk   contribs)	{ {File  description = 8. Non-granulomatous interstitial pneumonia/alveolitis. Late phase of granuloma formation. The lesion becomes more compact and better defined.  author = Yale Rosen, M.D.  source = <a href="http://granuloma.homestead.com/Development.html">http://granuloma.homestead.com/Development.html</a>  date = 2012-05-18 } }

You cannot overwrite this file.

## File usage

The following page uses this file:

- Sarcoidosis (pathology)