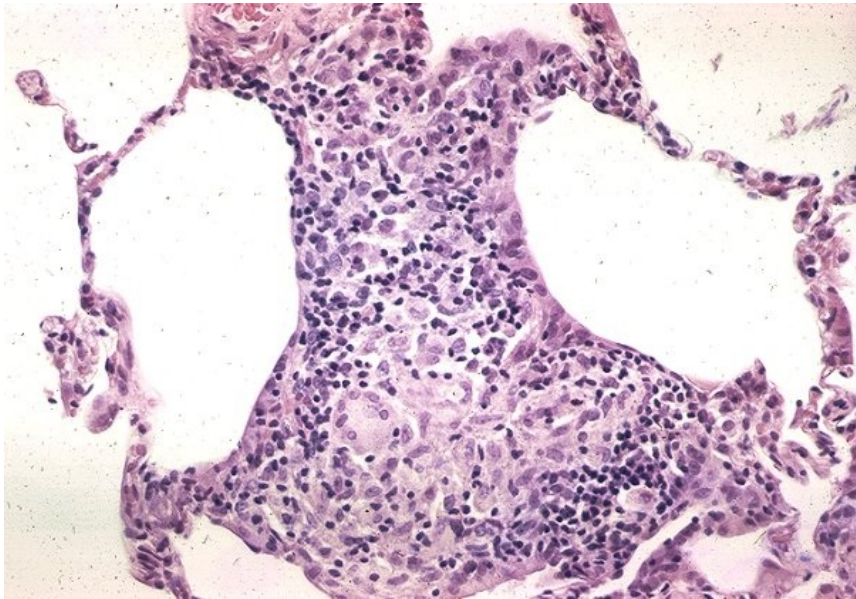


File:Sarkoidóza - vývoj granulomu 006.jpeg



No higher resolution available.

Sarkoidóza_-_vývoj_granulomu_006.jpeg (600 × 419 pixels, file size: 83 KB, MIME type: image/jpeg)

Summary

Description

7. Non-granulomatous interstitial pneumonia/alveolitis. Late phase of granuloma formation. The lesion becomes more compact and better defined.

Author

Yale Rosen, M.D.

Source

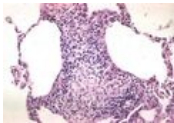
<http://granuloma.homestead.com/Development.html>

Date

2012-05-18

File history

Click on a date/time to view the file as it appeared at that time.

	Date/Time	Thumbnail	Dimensions	User	Comment
current	19:52, 12 May 2023		600 × 419 (83 KB)	Annavotrubova (talk contribs)	{{File description = 7. Non-granulomatous interstitial pneumonia/alveolitis. Late phase of granuloma formation. The lesion becomes more compact and better defined. author = Yale Rosen, M.D. source = http://granuloma.homestead.com/Development.html date = 2012-05-18 }}

You cannot overwrite this file.

File usage

The following page uses this file:

- Sarcoidosis (pathology)