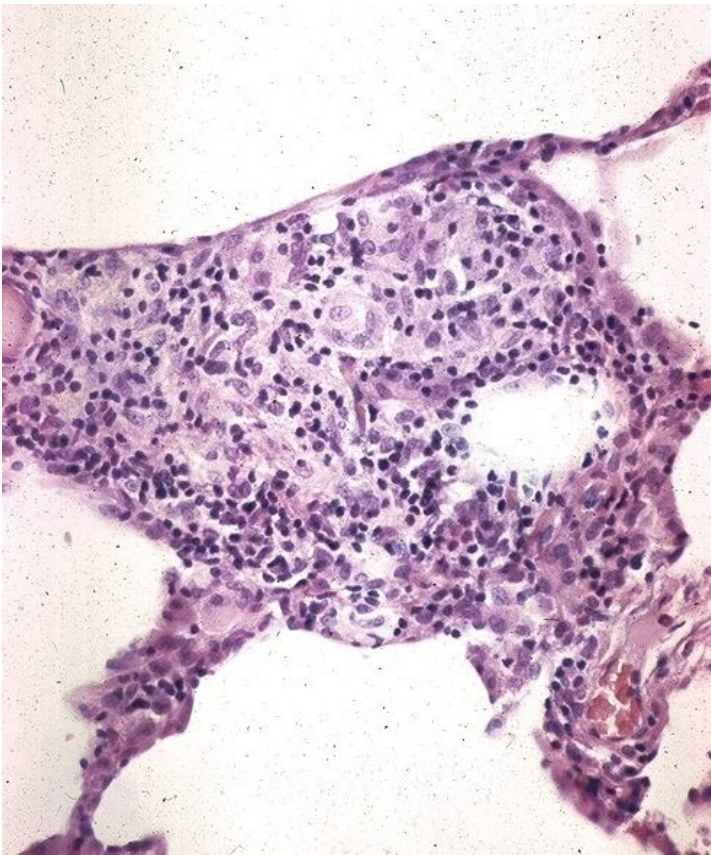


File:Sarkoidóza - vývoj granulomu 004.jpeg



No higher resolution available.

Sarkoidóza_-_vývoj_granulomu_004.jpeg (490 × 587 pixels, file size: 97 KB, MIME type: image/jpeg)

Summary

Description

5. Non-granulomatous interstitial pneumonia/alveolitis. A larger collection of macrophages with an admixture of lymphocytes. Growing granuloma.

Author

Yale Rosen, M.D.

Source

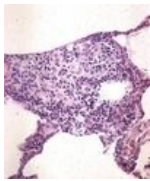
<http://granuloma.homestead.com/Development.html>

Date

2012-05-18

File history

Click on a date/time to view the file as it appeared at that time.

	Date/Time	Thumbnail	Dimensions	User	Comment
current	19:49, 12 May 2023		490 × 587 (97 KB)	Annavotrubova (talk contribs)	{ {File description = 5. Non-granulomatous interstitial pneumonia/alveolitis. A larger collection of macrophages with an admixture of lymphocytes. Growing granuloma. author = Yale Rosen, M.D. source = http://granuloma.homestead.com/Development.html date = 2012-05-18 } }

You cannot overwrite this file.

File usage

The following page uses this file:

- Sarcoidosis (pathology)