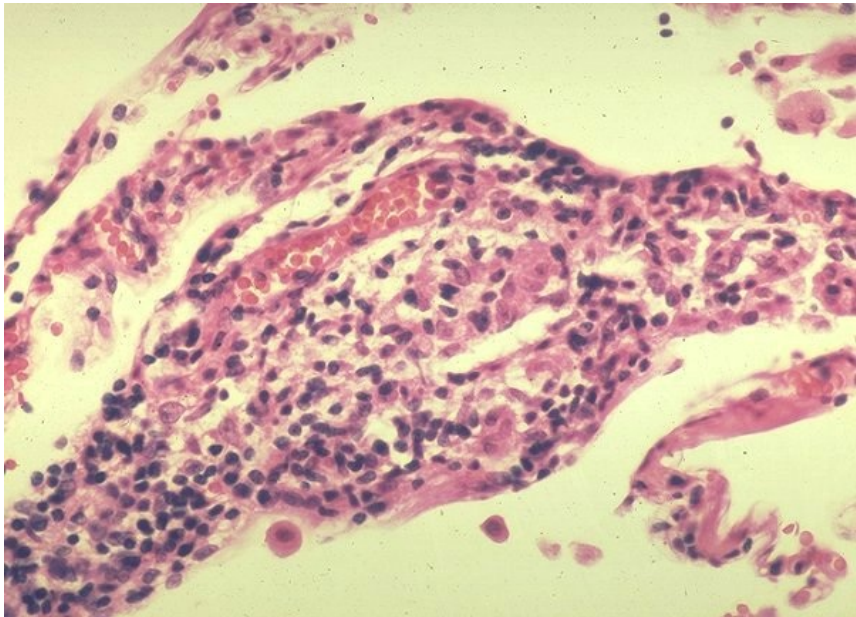


# File:Sarkoidóza - vývoj granulomu 003.jpeg



No higher resolution available.

Sarkoidóza - vývoj granulomu 003.jpeg (600 × 432 pixels, file size: 67 KB, MIME type: image/jpeg)

## Summary

### Description

4. Non-granulomatous interstitial pneumonia/alveolitis. A small collection of macrophages. Early granuloma formation.

### Author

Yale Rosen, M.D.

### Source

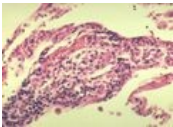
<http://granuloma.homestead.com/Development.html>

### Date

2012-05-18

## File history

Click on a date/time to view the file as it appeared at that time.

	Date/Time	Thumbnail	Dimensions	User	Comment
current	<b>20:47, 12 May 2023</b>		600 × 432 (67 KB)	Annavotrubova (talk   contribs)	{{ File  description = 4. Non-granulomatous interstitial pneumonia/alveolitis. A small collection of macrophages. Early granuloma formation.  author = Yale Rosen, M.D.  source = <a href="http://granuloma.homestead.com/Development.html">http://granuloma.homestead.com/Development.html</a>  date = 2012-05-18 }}

You cannot overwrite this file.

## File usage

The following page uses this file:

- Sarcoidosis (pathology)