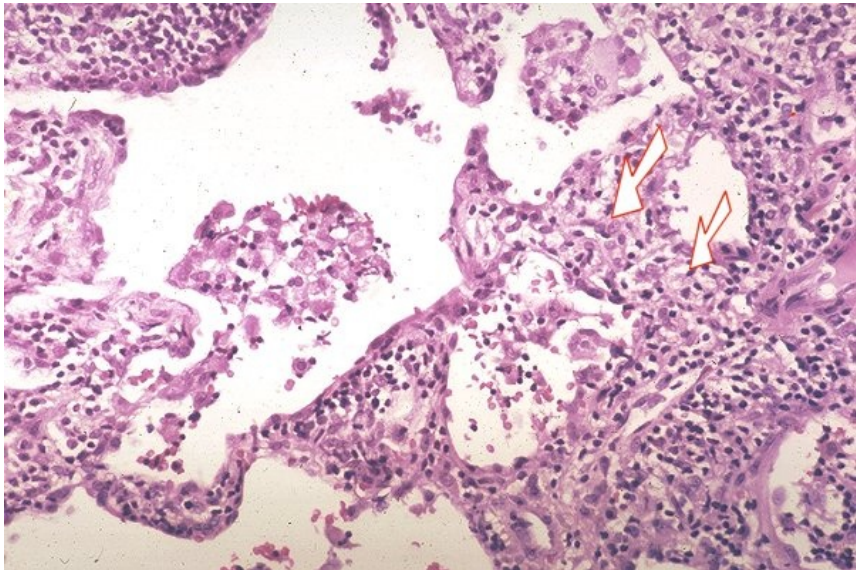


# File:Sarkoidóza - vývoj granulomu 002.jpeg



No higher resolution available.

Sarkoidóza\_-\_vývoj\_granulomu\_002.jpeg (600 × 399 pixels, file size: 91 KB, MIME type: image/jpeg)

## Summary

### Description

3. Non-granulomatous interstitial pneumonia/alveolitis. Arrows indicate small collections of macrophages. Early granuloma formation..

### Author

Yale Rosen, M.D.

### Source

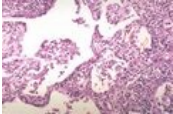
<http://granuloma.homestead.com/Development.html>

### Date

2012-05-18

## File history

Click on a date/time to view the file as it appeared at that time.

	Date/Time	Thumbnail	Dimensions	User	Comment
current	19:45, 12 May 2023		600 × 399 (91 KB)	Annavotrubova (talk   contribs)	{{File  description = 3. Non-granulomatous interstitial pneumonia/alveolitis. Arrows indicate small collections of macrophages. Early granuloma formation..  author = Yale Rosen, M.D.  source = <a href="http://granuloma.homestead.com/Development.html">http://granuloma.homestead.com/Development.html</a>  date = 2012-05-18 }}

You cannot overwrite this file.

## File usage

The following page uses this file:

- Sarcoidosis (pathology)