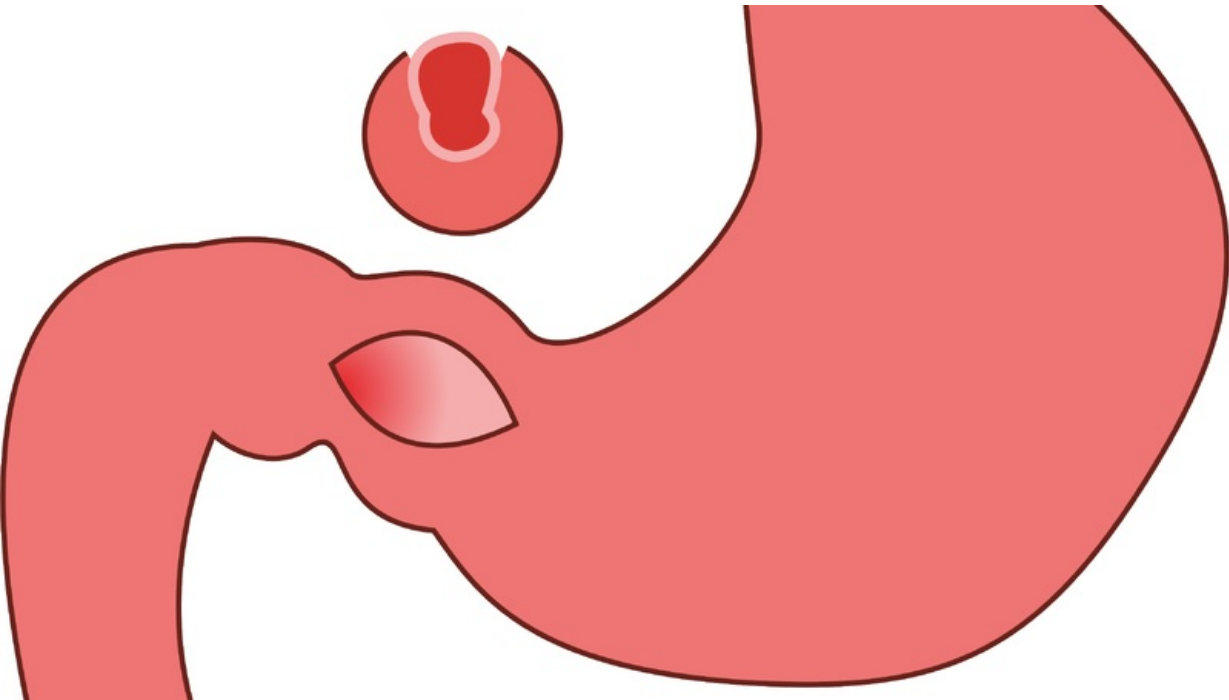


File:Pylorostenóza4.png



Size of this preview: 800 × 451 pixels.

Original file (2,700 × 1,521 pixels, file size: 143 KB, MIME type: image/png)

 [Open in Media Viewer](#) 

Summary

Description
pylorostenosis - result of pyloromyotomy


Author
Adnav

Source
own work

Date
2014-04-14

File history

Click on a date/time to view the file as it appeared at that time.

	Date/Time	Thumbnail	Dimensions	User	Comment
current	01:47, 18 January 2022		2,700 × 1,521 (143 KB)	MartinRuzicka (talk contribs)	<div>{{File description = pylorostenosis - result of pyloromyotomy author = Adnav source = own work date = 2014-04-14 }}</div>

You cannot overwrite this file.

File usage

The following page uses this file:

- Congenital defects of the gastrointestinal tract

Metadata

This file contains additional information, probably added from the digital camera or scanner used to create or digitize it.

If the file has been modified from its original state, some details may not fully reflect the modified file.

Author	Ulead Systems, Inc.
--------	---------------------