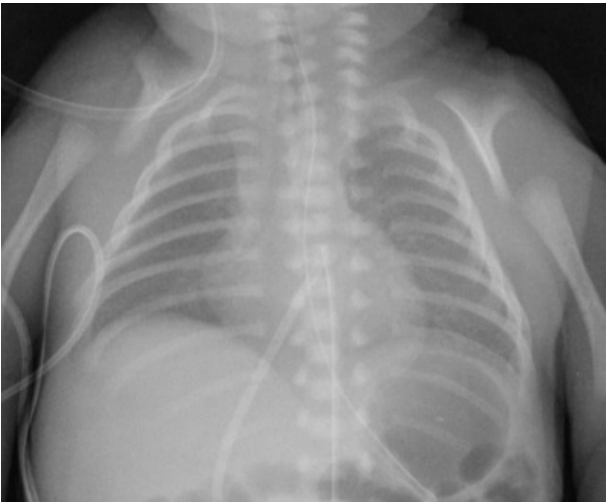


File:Premature neonate with clavicle agenesis in cleidocranial dysplasia..png



No higher resolution available.

Premature_neonate_with_clavicle_agenesis_in_cleidocranial_dysplasia..png (393 × 325 pixels, file size: 89 KB, MIME type: image/png)

cleidocranial dysplasia.

File history

Click on a date/time to view the file as it appeared at that time.

	Date/Time	Thumbnail	Dimensions	User	Comment
current	18:47, 16 March 2023		393 × 325 (89 KB)	Shana (talk contribs)	

You cannot overwrite this file.

File usage

The following page uses this file:

- Cleidocranial dysplasia

Metadata

This file contains additional information, probably added from the digital camera or scanner used to create or digitize it.

If the file has been modified from its original state, some details may not fully reflect the modified file.