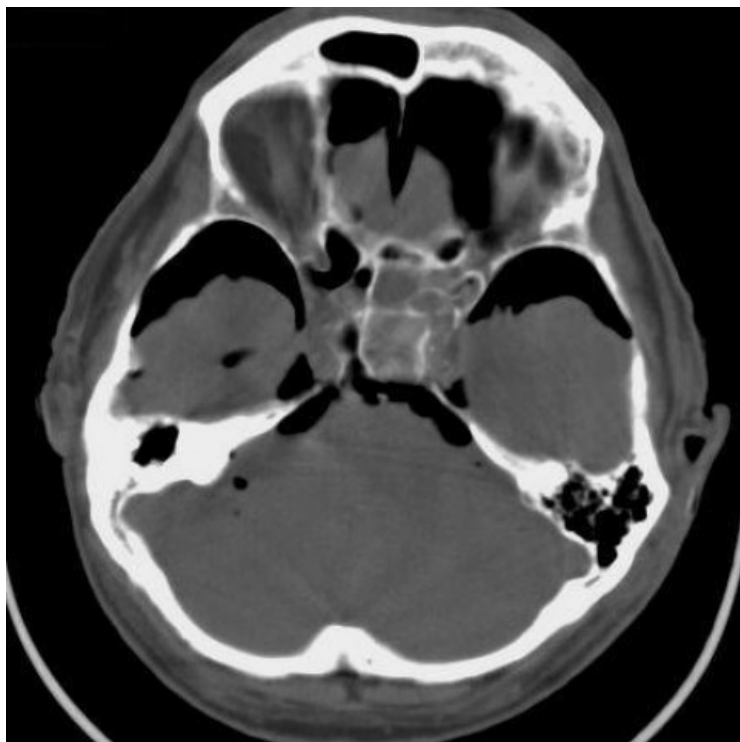


File:Pneumocephalus 1.png



No higher resolution available.

Pneumocephalus_1.png (480 × 480 pixels, file size: 149 KB, MIME type: image/png)


Summary

**Please choose
a more precise name
for your image.** |description = CT Post traumatic pneumocephalus |author = Kontaki T

et al |source = <https://www.eurorad.org/case/13764> |date = 07/08/2022 }}

File history

Click on a date/time to view the file as it appeared at that time.

	Date/Time	Thumbnail	Dimensions	User	Comment
current	12:38, 7 August 2022		480 × 480 (149 KB)	Saronw (talk contribs)	File:File.png description = CT Post traumatic pneumocephalus author = Kontaki T et al source = https://www.eurorad.org/case/13764 date = 07/08/2022 }}

You cannot overwrite this file.

File usage

The following file is a duplicate of this file (more details):

- File:Pneumocephalus.png

There are no pages that use this file.

Metadata

This file contains additional information, probably added from the digital camera or scanner used to create or digitize it.

If the file has been modified from its original state, some details may not fully reflect the modified file.