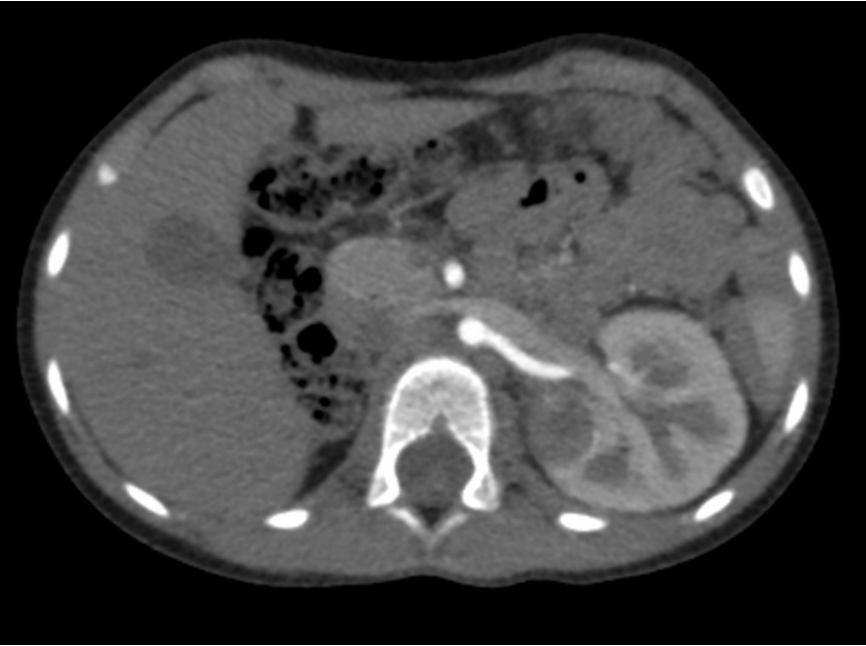


File:Nefroblastom solitarni zdvojena ledvina.png



No higher resolution available.

Nefroblastom_solitarni_zdvojena_ledvina.png (715 × 531 pixels, file size: 280 KB, MIME type: image/png)

Summary

Description
CT scan - nephroblastoma in a 4-year-old patient with a solitary double kidney

Author
Reichs

Source
https://www.wikiskripta.eu/w/Soubor:Nefroblastom_solitarni_zdvojena_ledvina.png

Date
30.10.2022

File history

Click on a date/time to view the file as it appeared at that time.

	Date/Time	Thumbnail	Dimensions	User	Comment
current	19:23, 30 October 2022		715 × 531 (280 KB)	S.Filonova (talk contribs)	{ {File description = CT scan - nephroblastoma in a 4-year-old patient with a solitary double kidney author = Reichs source = https://www.wikiskripta.eu/w/Soubor:Nefroblastom_solitarni_zdvojena_ledvina.png date = 30.10.2022 } }

You cannot overwrite this file.

File usage

The following page uses this file:

- Wilms' tumor

Metadata

This file contains additional information, probably added from the digital camera or scanner used to create or digitize it. If the file has been modified from its original state, some details may not fully reflect the modified file.