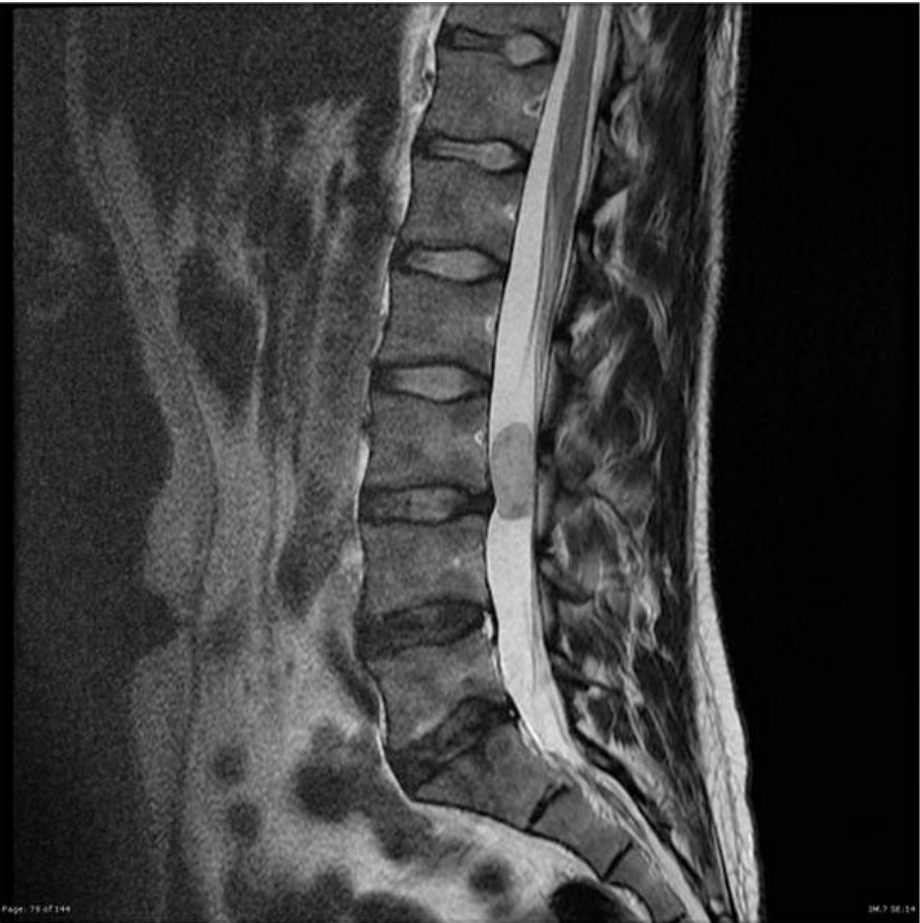

File:Myxo spinal.jpg



Size of this preview: 600 × 600 pixels.

Original file (630 × 630 pixels, file size: 61 KB, MIME type: image/jpeg)

 **Open in Media Viewer** 

Summary

- Description**

Write a description here
- Author**

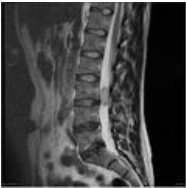
Author's name and surname
- Source**

Source web address or "own work"
- Date**

Date

File history

Click on a date/time to view the file as it appeared at that time.

	Date/Time	Thumbnail	Dimensions	User	Comment
current	22:45, 18 February 2022		630 × 630 (61 KB)	LauraKuz (talk contribs)	<div><div><div><div><div><div>{{File description = Write a description here author = Author's name and surname source = Source web address or "own work" date = Date }}</div></div></div></div></div></div>

You cannot overwrite this file.

File usage

The following 2 pages use this file:

- Ependymoma
- Tumors of cerebellum and IV. ventricle in adults