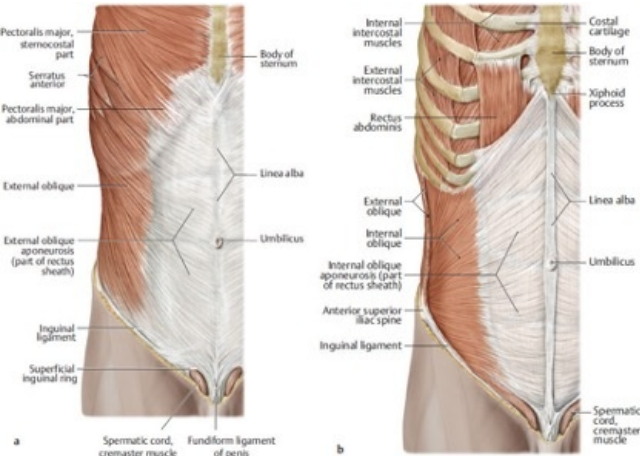


# File:Muscles of abdominal wall.jpg



No higher resolution available.

Muscles\_of\_abdominal\_wall.jpg (417 × 297 pixels, file size: 39 KB, MIME type: image/jpeg)

## Summary

### Description

Muscles of the abdominal wall. Right side, anterior view. Superficial abdominal wall muscles. Removed: external oblique, pectoralis major, and serratus anterior.

### Author

Schuenke M, Schulte E, Schumacher U. THIEME Atlas of Anatomy. General Anatomy and Musculoskeletal System. Illustrations by Voll M and Wesker K. 3rd ed. New York: Thieme Medical Publishers; 2020.

### Source

: 3.2.1 Muscles of the Anterolateral Wall. In: Wikenheiser J, Voll M, Wesker K, ed. Clinical Anatomy, Histology, Embryology, and Neuroanatomy: An Integrated Textbook. 1st Edition

### Date

27.03.2024

## File history

Click on a date/time to view the file as it appeared at that time.

	Date/Time	Thumbnail	Dimensions	User	Comment
current	<b>19:57, 27 March 2024</b>		417 × 297 (39 KB)	Shaked.Fru (talk   contribs)	{{File  description = Muscles of the abdominal wall. Right side, anterior view. Superficial abdominal wall muscles. Removed: external oblique, pectoralis major, and serratus anterior.  author = Schuenke M, Schulte E, Schumacher U. THIEME Atlas of Anatomy. General Anatomy and Musculoskeletal System. Illustrations by Voll M and Wesker K. 3rd ed. New York: Thieme Medical Publishers; 2020.  source = : 3.2.1 Muscles of the Anterolateral Wall. In: Wikenheiser J, Voll M, Wesker K, ed. Clin...

You cannot overwrite this file.

## File usage

The following page uses this file:

- Abdominal wall - Function, Muscles, fascias

## Metadata

This file contains additional information, probably added from the digital camera or scanner used to create or digitize it.

If the file has been modified from its original state, some details may not fully reflect the modified file.