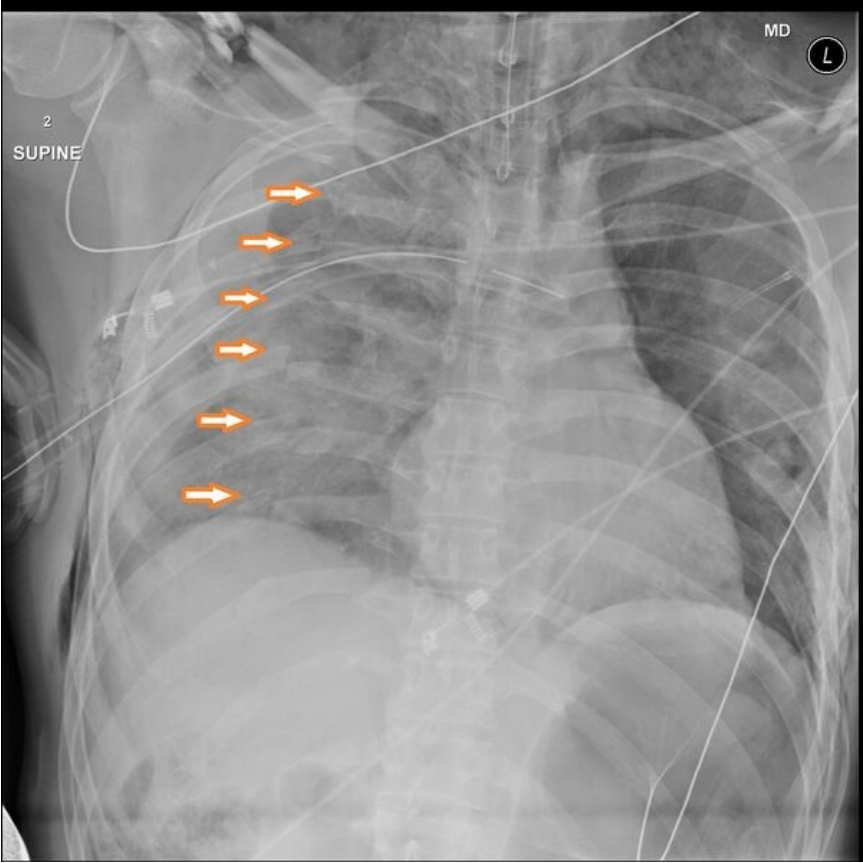


# File:Multiple-rib-fracture.jpg



Size of this preview: 600 × 600 pixels.

Original file (1,024 × 1,024 pixels, file size: 210 KB, MIME type: image/jpeg)

 [Open in Media Viewer](#) 

## Summary

### Description

Multiple rib fracture

### Author

Mr Andrew Murphy

### Source

Case courtesy of Mr Andrew Murphy, [Radiopaedia.org](https://radiopaedia.org/). From the case <https://radiopaedia.org/cases/47158> rID: 47158

### Date


2017-10-22

## Licensing

 Creative Commons Attribution-ShareAlike 4.0 Unported (<http://creativecommons.org/licenses/by-sa/4.0/deed.en>)

## File history

Click on a date/time to view the file as it appeared at that time.

|         | Date/Time               | Thumbnail   | Dimensions             | User                   | Comment  |
|---------|-------------------------|---|------------------------|------------------------|--|
| current | 12:53, 17 December 2022 |  | 1,024 × 1,024 (210 KB) | Mstp (talk   contribs) | { {File  description = Multiple rib fracture  author = Mr Andrew Murphy  source = Case courtesy of Mr Andrew Murphy, <a href="https://radiopaedia.org/">Radiopaedia.org</a> . From the case <a href="https://radiopaedia.org/cases/47158">https://radiopaedia.org/cases/47158</a> rID: 47158  date = 2017-10-22 }} |

You cannot overwrite this file.

## File usage

The following page uses this file:

- Rib fractures