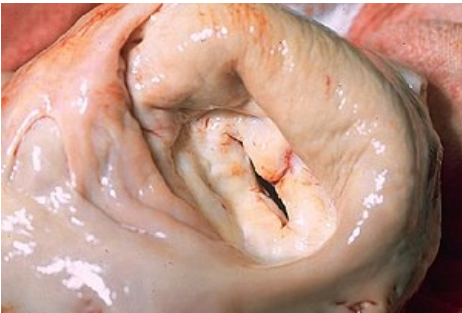

# File:Mitral stenosis, gross pathology 20G0015 lores.jpg



No higher resolution available.


Mitral\_stenosis,\_gross\_pathology\_20G0015\_lores.jpg (300 × 201 pixels, file size: 17 KB, MIME type: image/jpeg)

 **Open in Media Viewer** 

Mitral stenosis – thickened mitral valves

## File history

Click on a date/time to view the file as it appeared at that time.

	Date/Time	Thumbnail	Dimensions	User	Comment
current	13:05, 8 April 2023		300 × 201 (17 KB)	Sagihoz (talk   contribs)	

You cannot overwrite this file.

## File usage

The following 3 pages use this file:

- Mitral stenosis
- Valvular defects
- Valvular heart diseases