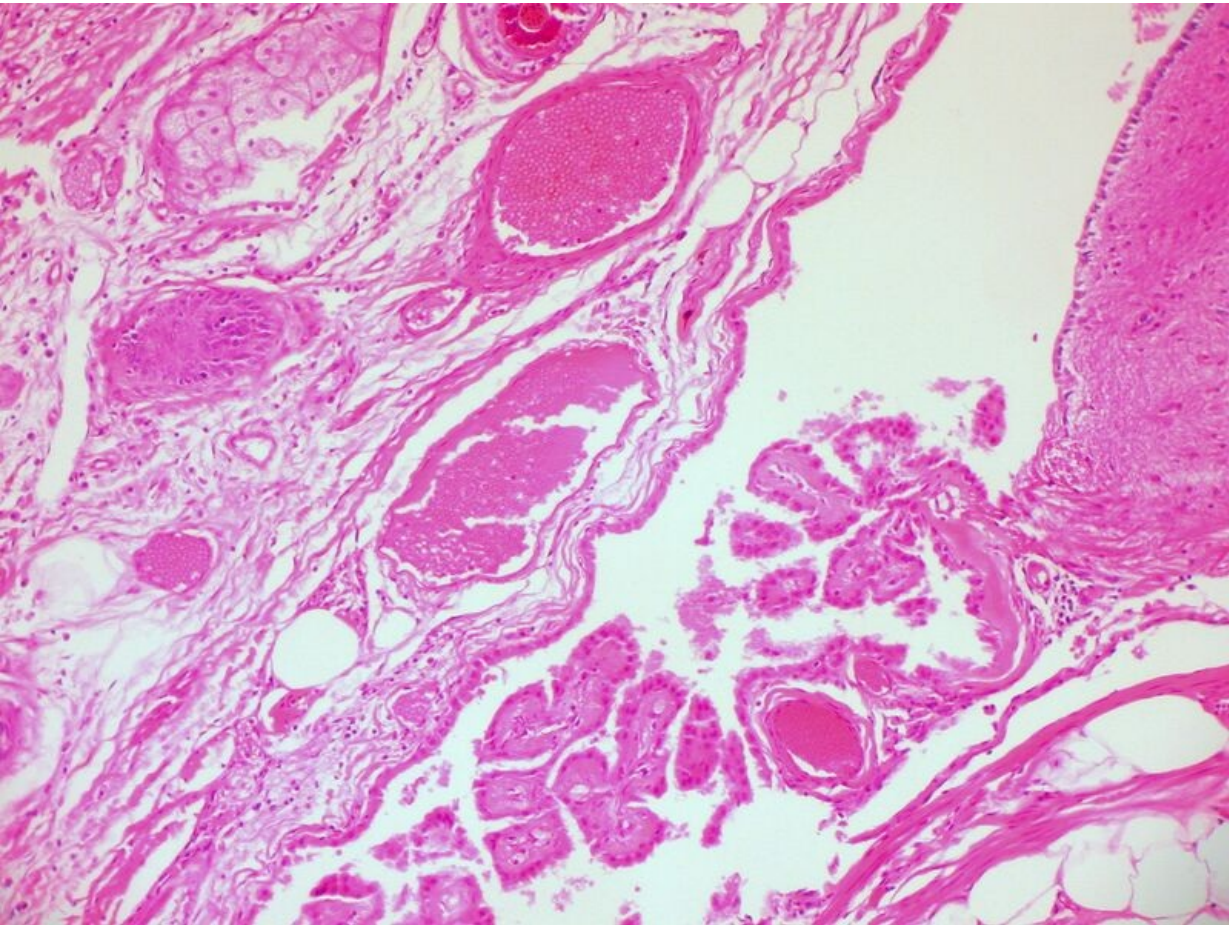


File:Mature Cystic Teratoma of the Ovary (3776273154).jpg



Size of this preview: 800 × 600 pixels.

Original file (2,048 × 1,536 pixels, file size: 1.28 MB, MIME type: image/jpeg)

Summary

Description

Write a description here

Author

Author's name and surname

Source

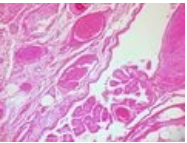
Source web address or "own work"

Date

Date

File history

Click on a date/time to view the file as it appeared at that time.

	Date/Time	Thumbnail	Dimensions	User	Comment
current	23:06, 29 November 2021		2,048 × 1,536 (1.28 MB)	Aly salam (talk contribs)	{{File description = Write a description here author = Author's name and surname source = Source web address or "own work" date = Date }}

You cannot overwrite this file.

File usage

The following file is a duplicate of this file (more details):

- File:Mature Cystic Teratoma of the Ovary (3776273154).jpg from Wikimedia Commons

The following page uses this file:

- Germinal tumors

Metadata

This file contains additional information, probably added from the digital camera or scanner used to create or digitize it.

If the file has been modified from its original state, some details may not fully reflect the modified file.

Camera manufacturer	NIKON
Camera model	E995
Exposure time	1/38 sec (0.026315789473684)
F Number	f/3.4
ISO speed rating	100
Date and time of data generation	12:19, 16 July 2009
Lens focal length	15.3 mm