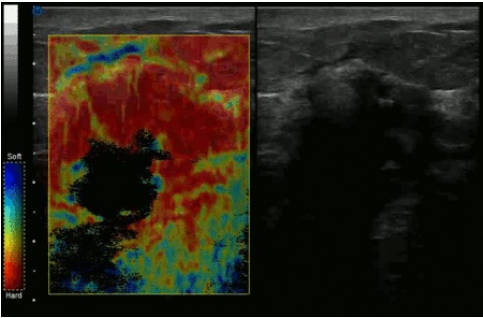


File:Manual compression elastography of invazive ductal carcinoma 00132.gif



No higher resolution available.

Manual_compression_elastography_of_invazive_ductal_carcinoma_00132.gif (450 × 293 pixels, file size: 972 KB, MIME type: image/gif, looped, 40 frames, 4.8 s)

Note: Due to technical limitations, thumbnails of high resolution GIF images such as this one will not be animated.

Summary

{{File |description = Invasive ductal carcinoma, manual compression elastography |author = |source = https://www.wikiskripta.eu/index.php?curid=49558#/media/Soubor:Manual_compression_elastography_of_invazive_ductal_carcinoma_00132.gif |date = 04.11.2022

File history

Click on a date/time to view the file as it appeared at that time.

	Date/Time	Thumbnail	Dimensions	User	Comment
current	22:12, 4 November 2022		450 × 293 (972 KB)	S.Filonova (talk contribs)	{ {File description = Invasive ductal carcinoma, manual compression elastography author = source = https://www.wikiskripta.eu/index.php?curid=49558#/media/Soubor:Manual_compression_elastography_of_invazive_ductal_carcinoma_00132.gif date = 04.11.2022

You cannot overwrite this file.

File usage

The following 2 pages use this file:

- Diagnostic use of ultrasound
- Elastography

Metadata

This file contains additional information, probably added from the digital camera or scanner used to create or digitize it.

If the file has been modified from its original state, some details may not fully reflect the modified file.