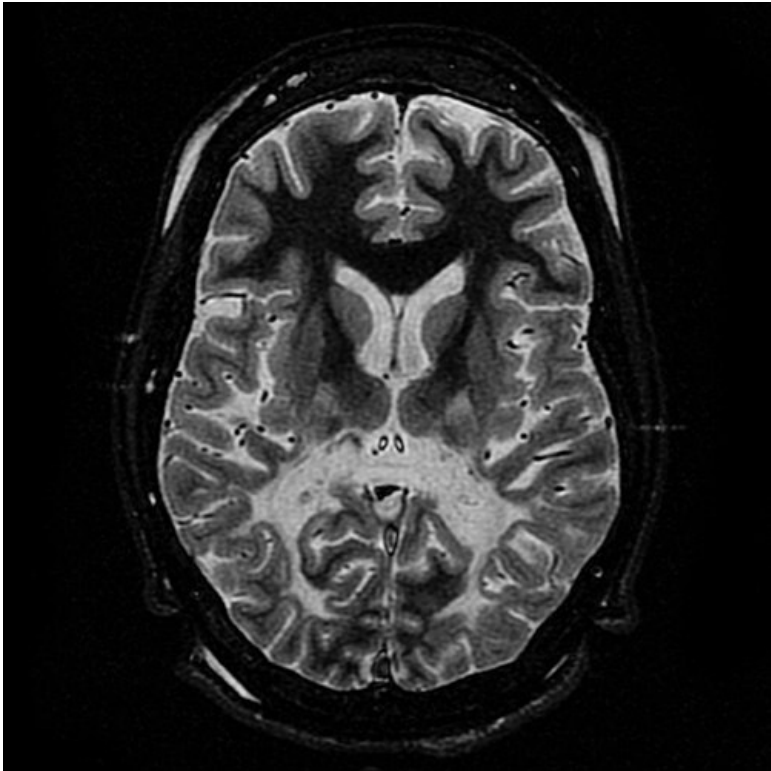


File:Imageyt.jpg



No higher resolution available.

Imageyt.jpg (500 × 500 pixels, file size: 42 KB, MIME type: image/jpeg)

X-ALD on MRI , T2 weighted image. White matter loss and hyperintense signal are evident in the occipital lobe. The white matter of the frontal lobe is spared

File history

Click on a date/time to view the file as it appeared at that time.

	Date/Time	Thumbnail	Dimensions	User	Comment
current	10:26, 16 November 2022		500 × 500 (42 KB)	Ali78 (talk contribs)	

You cannot overwrite this file.

File usage

The following page uses this file:

- X-linked adrenoleukodystrophy