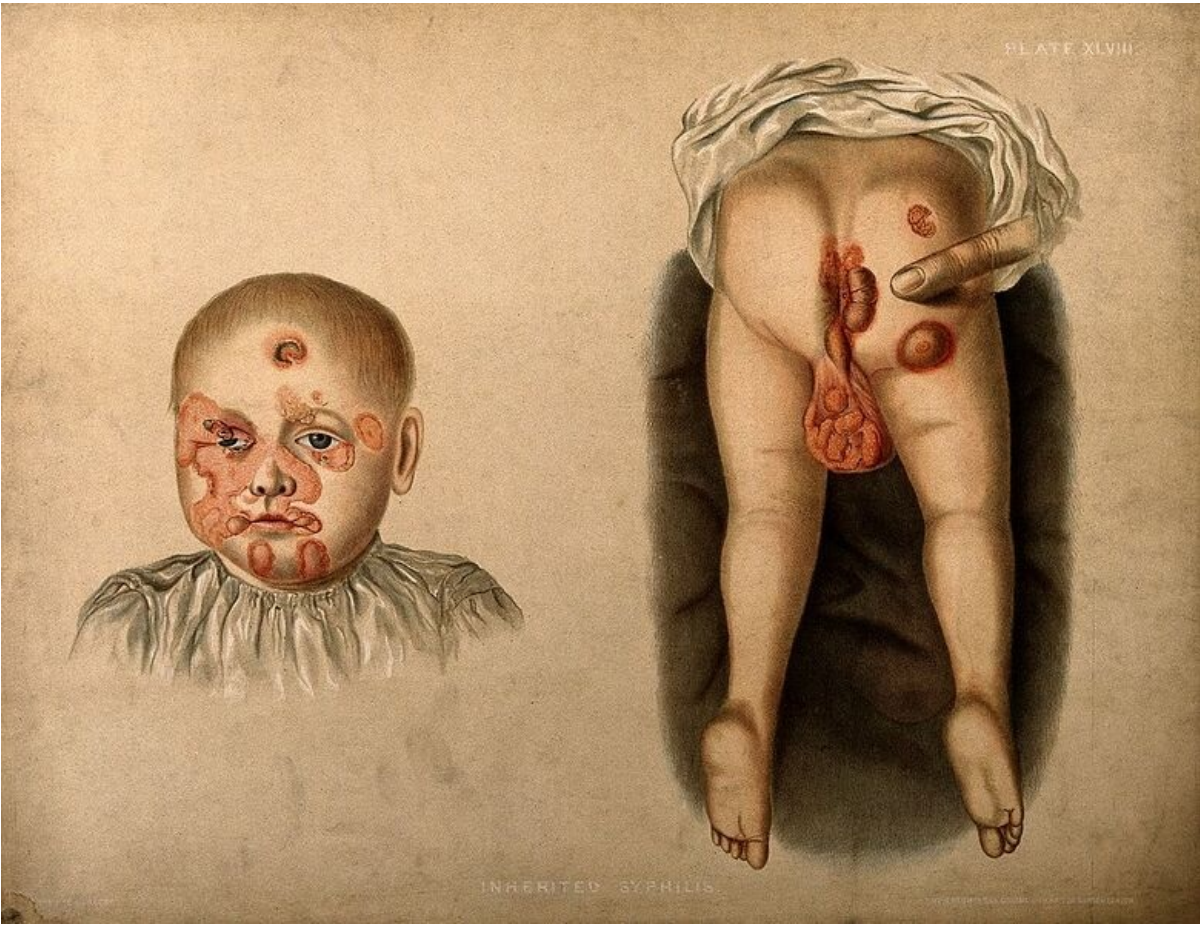


File:Hereditary syphilis; lesions face, buttocks, genitals, 1850 Wellcome V0010240.jpg



Size of this preview: 780 × 599 pixels.


Original file (1,024 × 787 pixels, file size: 602 KB, MIME type: image/jpeg)

 [Open in Media Viewer](#) 

Hereditary syphilis; lesions face, buttocks, genitals

File history

Click on a date/time to view the file as it appeared at that time.

	Date/Time	Thumbnail	Dimensions	User	Comment
current	23:27, 21 January 2022		1,024 × 787 (602 KB)	Hnilicovaeva (talk contribs)	

You cannot overwrite this file.

File usage

The following 3 pages use this file:

- Congenital syphilis
- Syphilis
- Syphilis (clinical picture)

Metadata

This file contains additional information, probably added from the digital camera or scanner used to create or digitize it.

If the file has been modified from its original state, some details may not fully reflect the modified file.