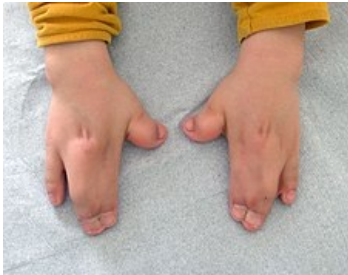

File:Hands in Apert syndrome.jpg




No higher resolution available.

Hands_in_Apert_syndrome.jpg (225 × 177 pixels, file size: 12 KB, MIME type: image/jpeg)

Syndactyly in Apert syndrome. Clinical picture of premature closure of cranial sutures, syndactyly on the legs and hands. Cause of mutation of the FGFR2 gene (AD) in the region 10q26.13

File history

Click on a date/time to view the file as it appeared at that time.

	Date/Time	Thumbnail	Dimensions	User	Comment
current	21:15, 15 March 2023		225 × 177 (12 KB)	Sam02 (talk contribs)	

You cannot overwrite this file.

File usage

The following page uses this file:

- Apert syndrome