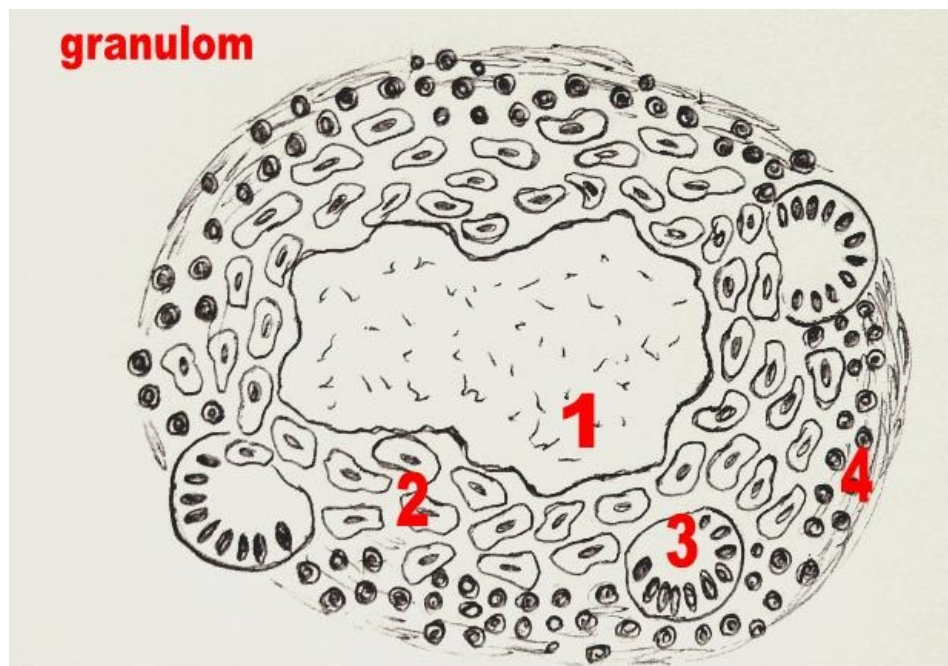


File:Granulom.jpg



1 – papršť ková nekróza; 2 – epiteloidní buňky; 3 – Langhansovy buňky; 4 – lem lymfocytů

No higher resolution available.

Granulom.jpg (615 × 464 pixels, file size: 62 KB, MIME type: image/jpeg)

 [Open in Media Viewer](#) 

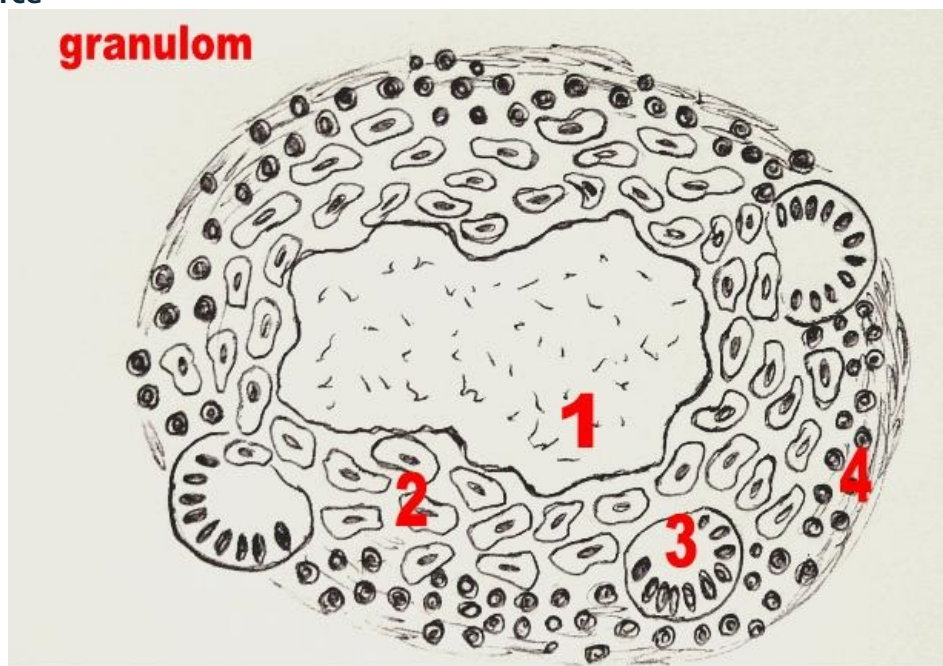
Description

Granuloma, scheme

Author

Adnav (<http://www.wikiskripta.eu/index.php/U%C5%BEivatel:Adnav>)

Source




1 – papršť ková nekróza; 2 – epiteloidní buňky; 3 – Langhansovy buňky; 4 – lem lymfocytů

Date


2011-01-16

Licensing

 Creative Commons Attribution 3.0 Czech Republic (<http://creativecommons.org/licenses/by/3.0/cz/deed.en>)

File history

Click on a date/time to view the file as it appeared at that time.

	Date/Time	Thumbnail	Dimensions	User	Comment
current	12:50, 3 April 2012		615 × 464 (62 KB)	Misa R (talk contribs)	{{File description = Granuloma, scheme source = http://www.wikiskripta.eu/images/3/32/Granulom.jpg date = 2011-01-16 author = Adnav license = {{cc by 3.0 cz}} }} Category:Pathology Category:Images

You cannot overwrite this file.

File usage

The following 2 pages use this file:

- Granuloma
- Tuberculosis (pathology)

Metadata

This file contains additional information, probably added from the digital camera or scanner used to create or digitize it.

If the file has been modified from its original state, some details may not fully reflect the modified file.