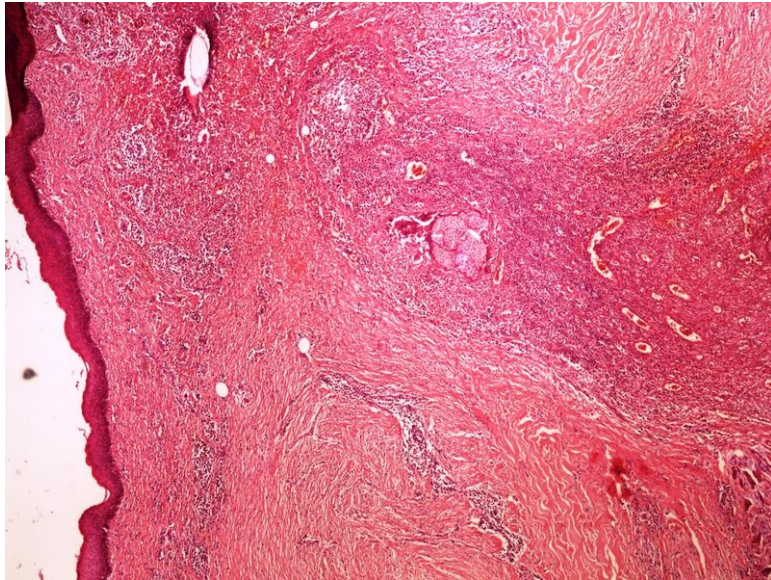


File:Foreign body granuloma obrovskobunecny granulom 4x.jpg



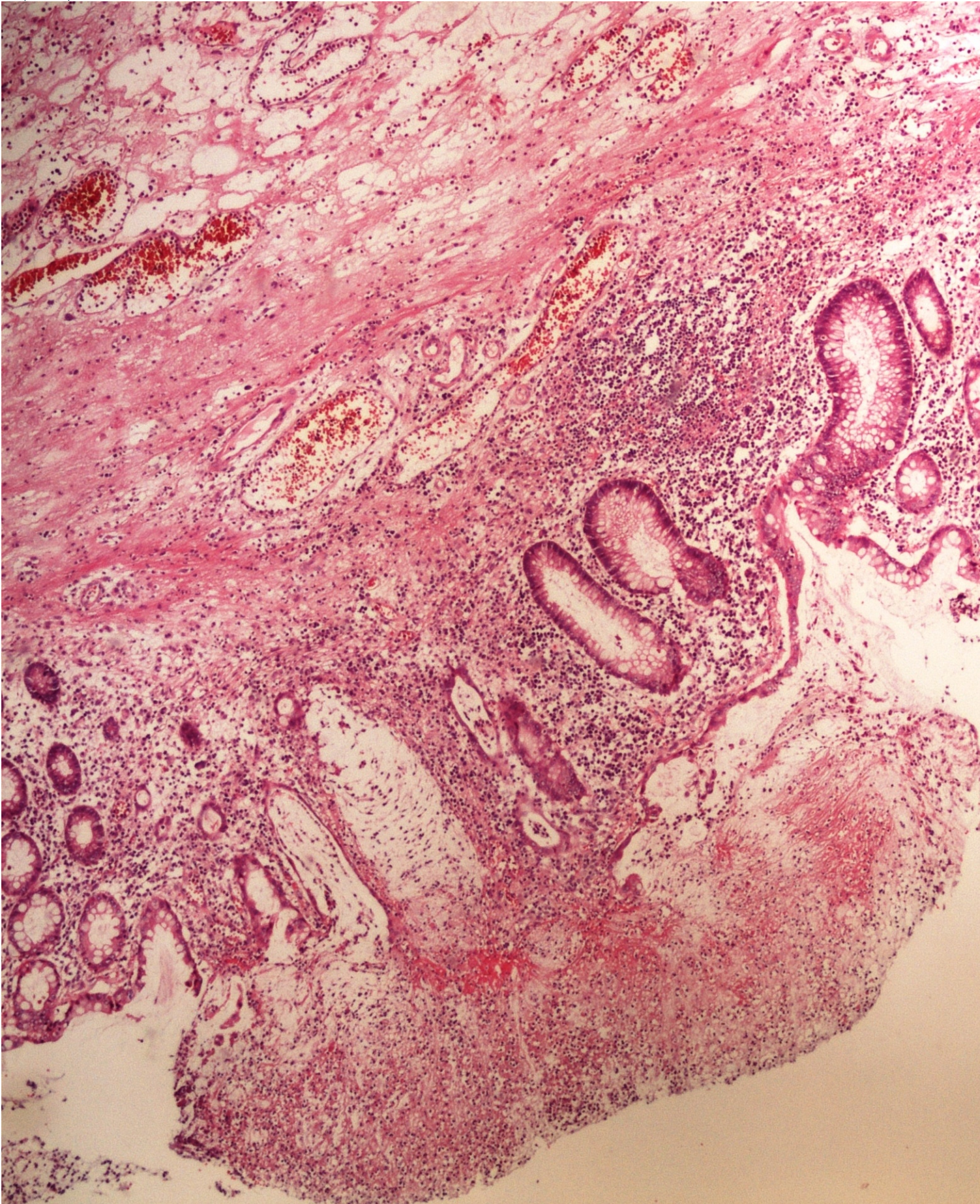
Size of this preview: 800 × 600 pixels.

Original file (2,560 × 1,920 pixels, file size: 3.83 MB, MIME type: image/jpeg)

 [Open in Media Viewer](#) 

Summary

Summary




Licensing

Licensing

File history

Click on a date/time to view the file as it appeared at that time.

	Date/Time	Thumbnail	Dimensions	User	Comment
current	01:55, 22 May 2023		2,560 × 1,920 (3.83 MB)	Rynard (talk contribs)	{ {File:Pseudomembranous colitis pablanova kolitis 4x.jpg author = Patologie3LF source = https://www.wikiskripta.eu/w/Soubor:Foreign_body_granuloma_obrovskobuncny_granulom_4x.jpg date = 20/05/2023 } }

You cannot overwrite this file.

File usage

The following 3 pages use this file:

- Module GFPP - Practice no. 7
- Module General basics of pathology and pathophysiology - Overview of preparations
- OZPP Module - Practice Number 7

Metadata

This file contains additional information, probably added from the digital camera or scanner used to create or digitize it.

If the file has been modified from its original state, some details may not fully reflect the modified file.