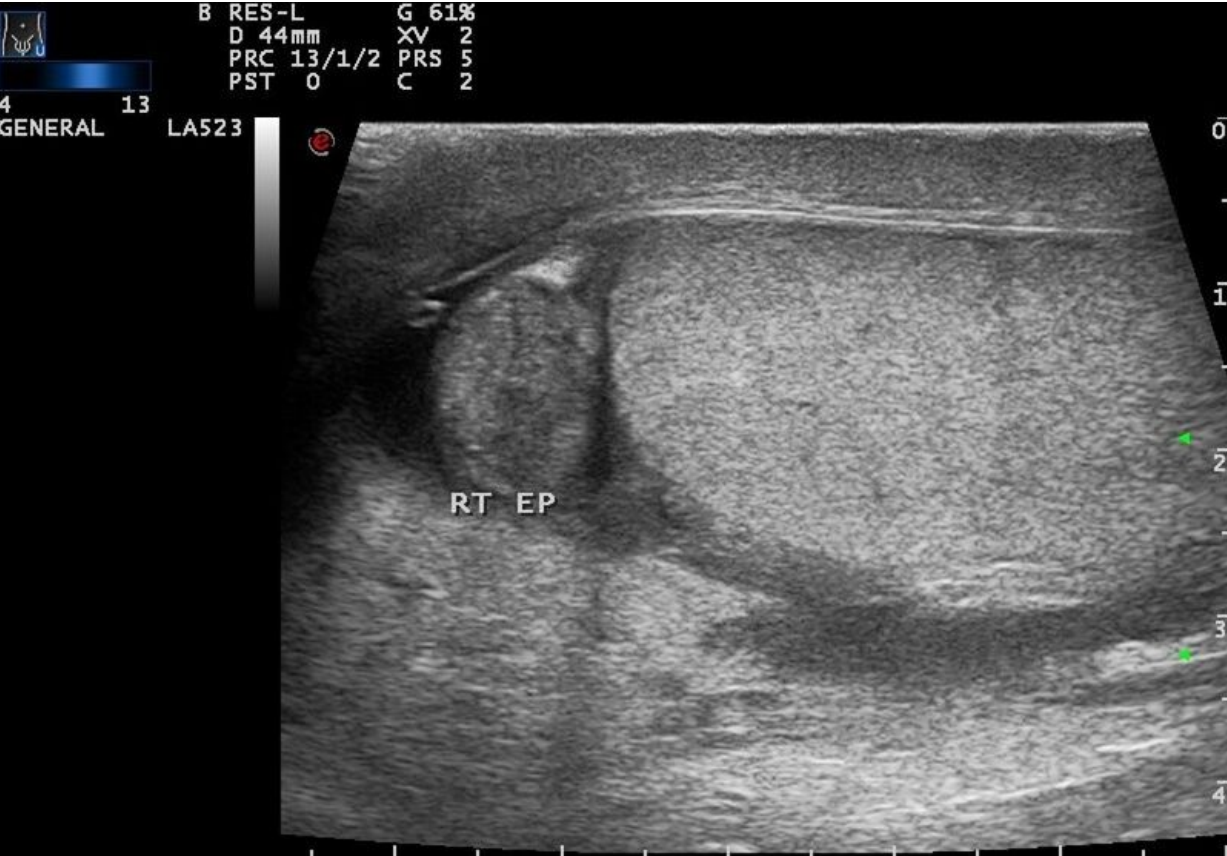

File:Epididymitis.jpg



Size of this preview: 800 × 555 pixels.

Original file (1,024 × 710 pixels, file size: 88 KB, MIME type: image/jpeg)

 [Open in Media Viewer](#) 

Summary

Description

epididymitis

Author

Dr. Fakhry Mahmoud Ebouda

Source


Case courtesy of Dr Fakhry Mahmoud Ebouda, <https://radiopaedia.org/> Radiopaedia.org. From the case <https://radiopaedia.org/cases/28648> rID: 28648

Date

Date

File history

Click on a date/time to view the file as it appeared at that time.

	Date/Time	Thumbnail	Dimensions	User	Comment
current	16:30, 16 May 2023		1,024 × 710 (88 KB)	Matinfalahi (talk contribs)	{{File description = epididymitis author = Dr. Fakhry Mahmoud Ebouda source = Case courtesy of Dr Fakhry Mahmoud Ebouda, https://radiopaedia.org/ Radiopaedia.org. From the case https://radiopaedia.org/cases/28648 rID: 28648 date = Date }}

You cannot overwrite this file.

File usage

The following page uses this file:

- Acute epididymitis