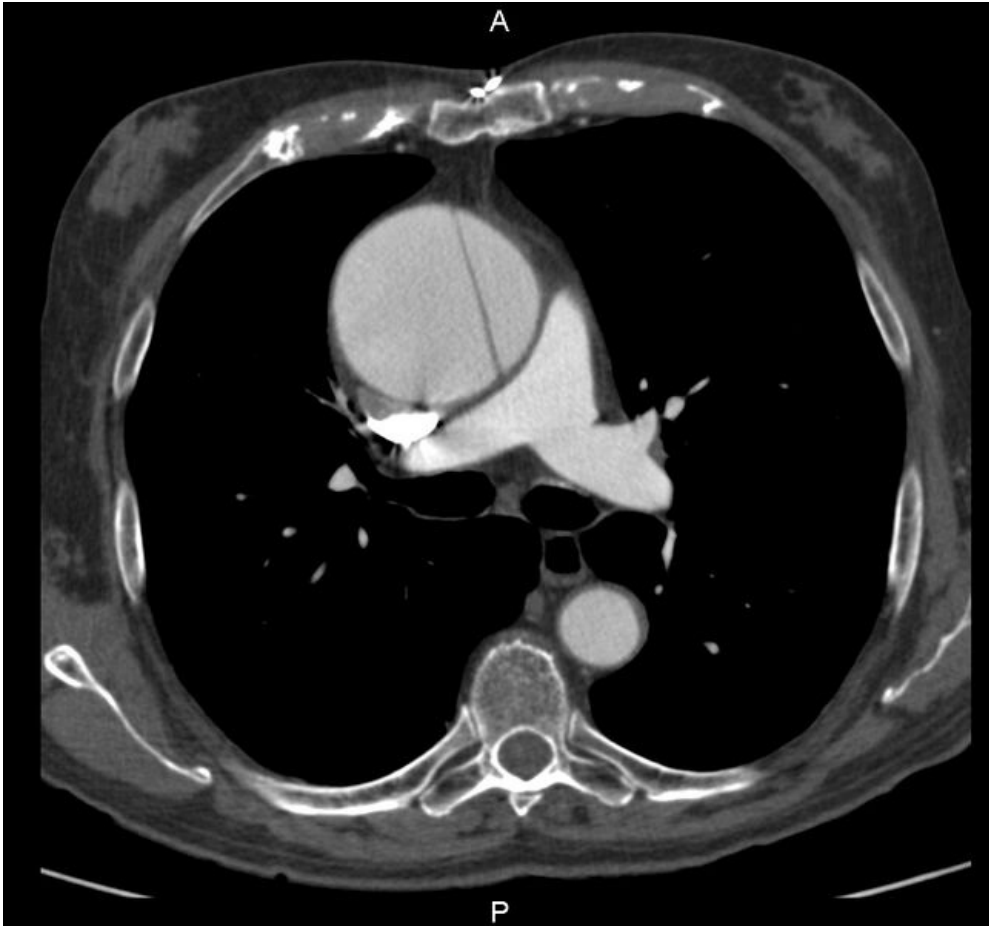

File:Dissection of ascending aorta.jpeg



Size of this preview: 642 × 600 pixels.

Original file (1,046 × 977 pixels, file size: 212 KB, MIME type: image/jpeg)

 [Open in Media Viewer](#)



Summary

Description
CT dissection of an aneurysmal ascending aorta

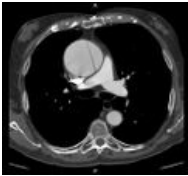
Author
FNHK radiology clinic

Source
FNHK radiology clinic

Date
2012-10-10

File history

Click on a date/time to view the file as it appeared at that time.

	Date/Time	Thumbnail	Dimensions	User	Comment
current	19:17, 1 April 2023		1,046 × 977 (212 KB)	JowelJ (talk contribs)	{{File description = CT dissection of an aneurysmal ascending aorta author = FNHK radiology clinic source = FNHK radiology clinic date = 2012-10-10 }}

You cannot overwrite this file.

File usage

The following file is a duplicate of this file (more details):

- File:Disekce ascendentní aorty.jpg

The following page uses this file:

- Dissection of the thoracic aorta