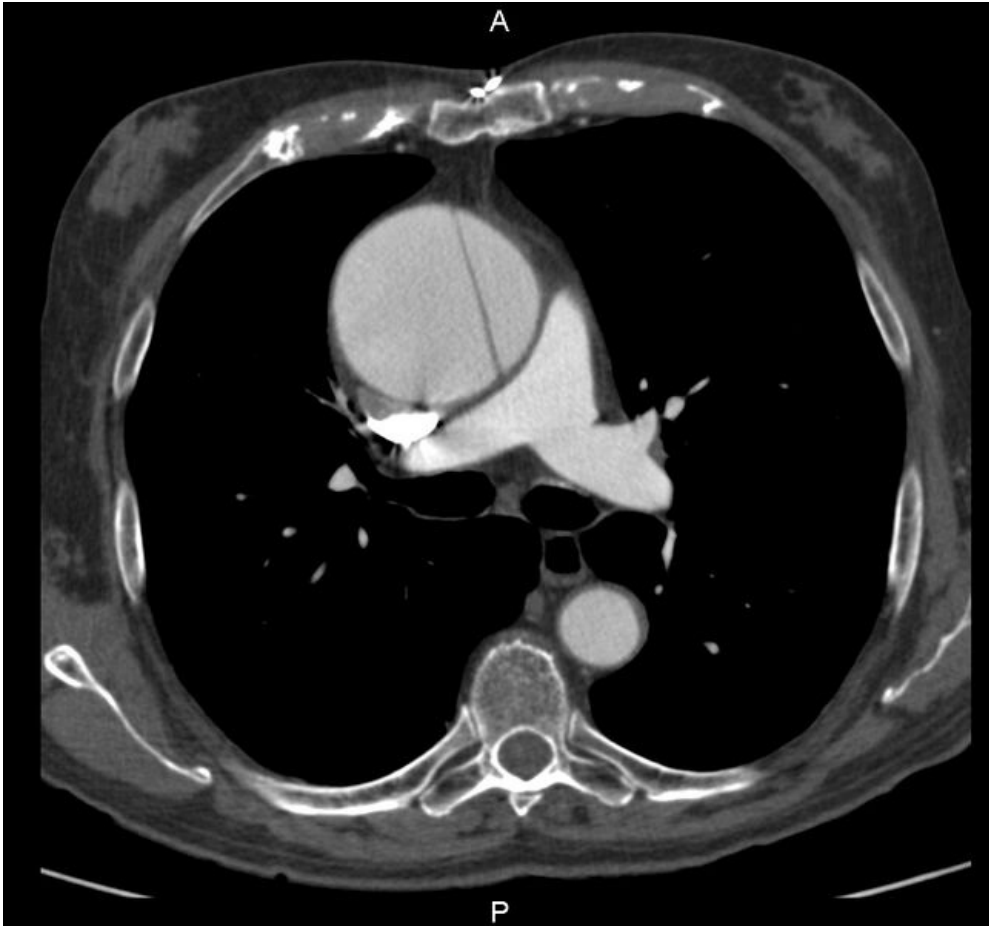

# File:Disekce ascendentní aorty.jpg



Size of this preview: 642 × 600 pixels.

Original file (1,046 × 977 pixels, file size: 212 KB, MIME type: image/jpeg)

 [Open in Media Viewer](#)



## Summary

### Description

Write a description here

### Author

Author's name and surname

### Source

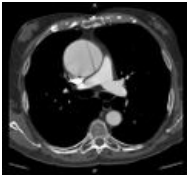
Source web address or "own work"

### Date

Date

## File history

Click on a date/time to view the file as it appeared at that time.

	Date/Time	Thumbnail	Dimensions	User	Comment
current	00:15, 30 November 2021		1,046 × 977 (212 KB)	Aly salam (talk   contribs)	{{File  description = Write a description here  author = Author's name and surname  source = Source web address or "own work"  date = Date }}

You cannot overwrite this file.

## File usage

The following file is a duplicate of this file (more details):

- File:Dissection of ascending aorta.jpeg

The following page uses this file:

- Thoracic aortic dissection