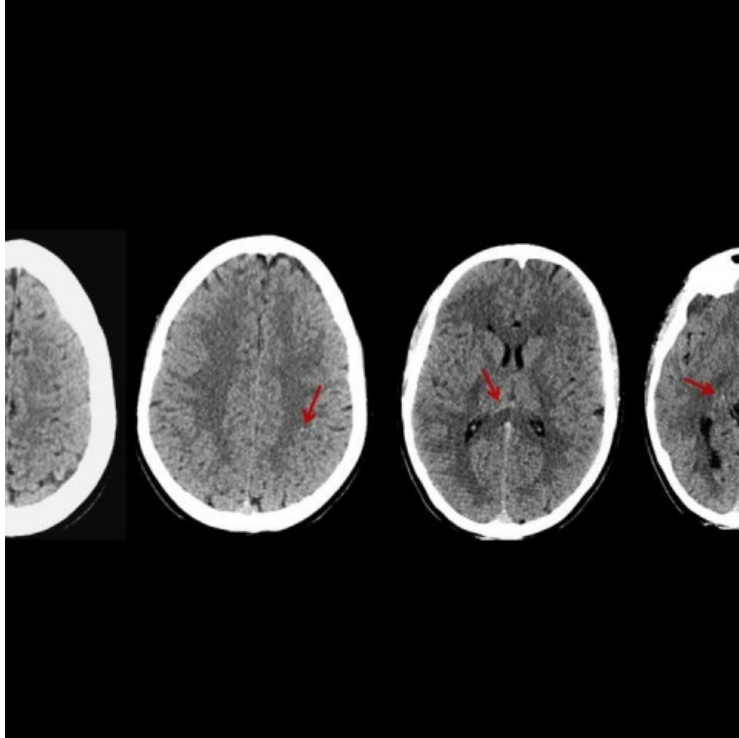


File:Diffuse axonal injury.png



No higher resolution available.

Diffuse_axonal_injury.png (480 × 480 pixels, file size: 102 KB, MIME type: image/png)

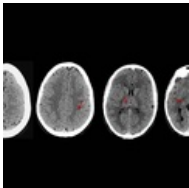
Summary

**Please choose
a more precise name
for your image.** [description = Hyperdense areas (red arrows) which are

microhaemorrhages due to diffuse axonal injury |author = Matifall et al. |source =
<https://www.eurorad.org/case/14466> |date = 07/08/2022 }}

File history

Click on a date/time to view the file as it appeared at that time.

	Date/Time	Thumbnail	Dimensions	User	Comment
current	12:21, 7 August 2022		480 × 480 (102 KB)	Saronw (talk contribs)	File:File.jpg description = Hyperdense areas (red arrows) which are microhaemorrhages due to diffuse axonal injury author = Matifall et al. source = https://www.eurorad.org/case/14466 date = 07/08/2022 }}

You cannot overwrite this file.

File usage

The following page uses this file:

- Craniocerebral trauma

Metadata

This file contains additional information, probably added from the digital camera or scanner used to create or digitize it.

If the file has been modified from its original state, some details may not fully reflect the modified file.