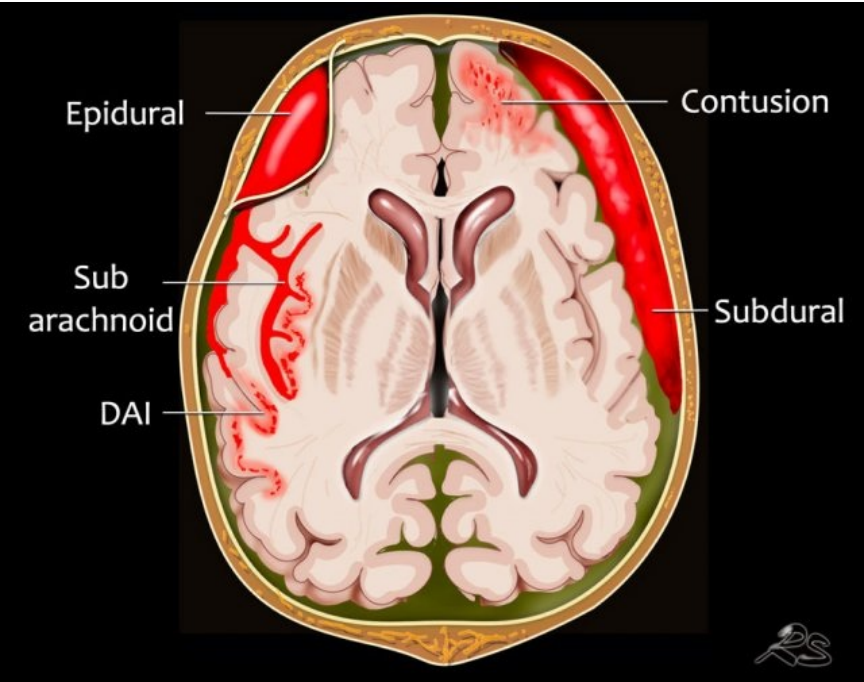


File:Craniocerebral hematoma.jpg



No higher resolution available.

Craniocerebral_hematoma.jpg (640 × 503 pixels, file size: 55 KB, MIME type: image/jpeg)

Summary

Description

Types of craniocerebral bleeding

Author

Bucker et al

Source

<https://radiologyassistant.nl/neuroradiology/hemorrhage/traumatic-intracranial-haemorrhage>

Date


August 7 2022

Licensing

Public domain

File history

Click on a date/time to view the file as it appeared at that time.

	Date/Time	Thumbnail	Dimensions	User	Comment
current	12:46, 7 August 2022		640 × 503 (55 KB)	Saronw (talk contribs)	{ {File description = Types of craniocerebral bleeding author = Bucker et al source = https://radiologyassistant.nl/neuroradiology/hemorrhage/traumatic-intracranial-haemorrhage date = August 7 2022 } }

You cannot overwrite this file.

File usage

There are no pages that use this file.

Metadata

This file contains additional information, probably added from the digital camera or scanner used to create or digitize it.

If the file has been modified from its original state, some details may not fully reflect the modified file.