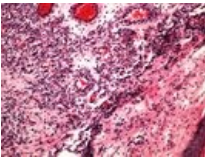


# File:Capillary haemangioma skin kapilarni hemangiom kuze 20x.jpg



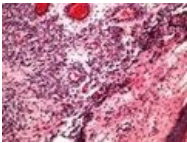
No higher resolution available.

Capillary\_haemangioma\_skin\_kapilarni\_hemangiom\_kuze\_20x.jpg (133 × 100 pixels, file size: 8 KB, MIME type: image/jpeg)

Capillary haemangioma skin kapilarni hemangiom kuze 20x

## File history

Click on a date/time to view the file as it appeared at that time.

	Date/Time	Thumbnail	Dimensions	User	Comment
current	14:10, 15 May 2023		133 × 100 (8 KB)	Olya.ivanova (talk   contribs)	

You cannot overwrite this file.

## File usage

The following 3 pages use this file:

- Module GFPP - Practice no. 10
- Module General basics of pathology and pathophysiology - Overview of preparations
- OZPP module - Practicum No. 10

## Metadata

This file contains additional information, probably added from the digital camera or scanner used to create or digitize it.

If the file has been modified from its original state, some details may not fully reflect the modified file.