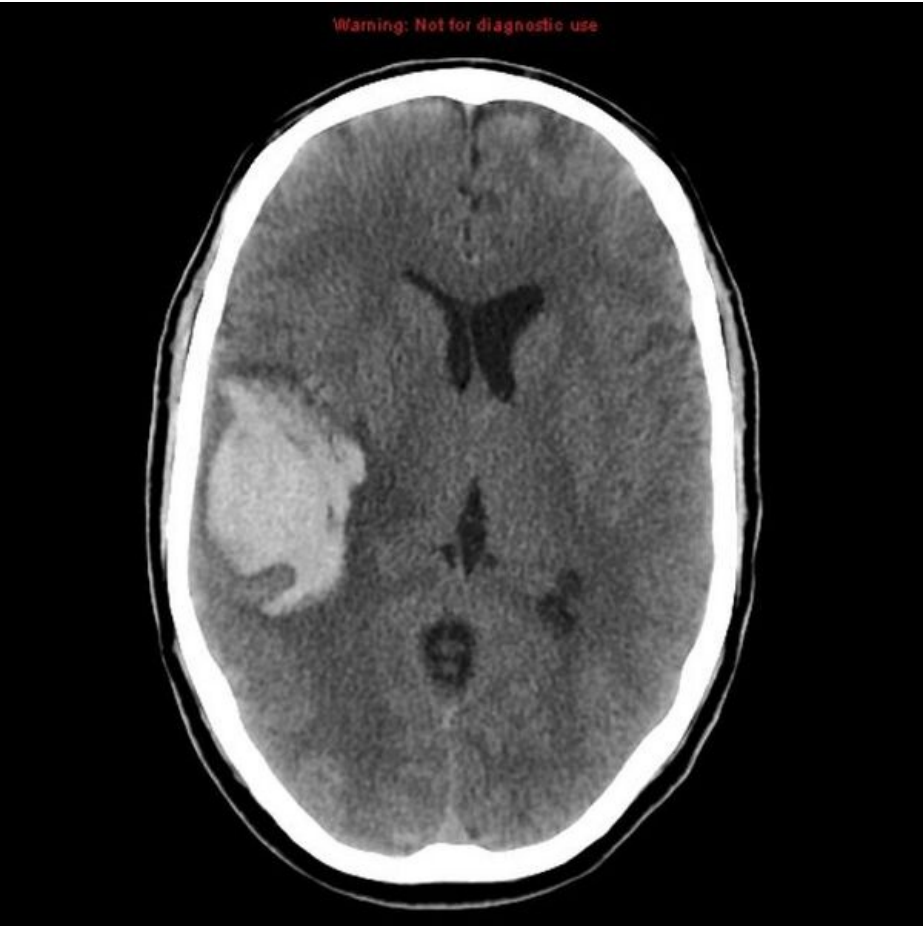

File:CT brainAVM non-contrast hematoma.jpg



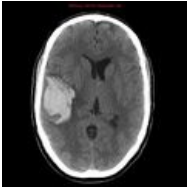
Size of this preview: 600 × 600 pixels.

Original file (630 × 630 pixels, file size: 36 KB, MIME type: image/jpeg)

CT without contrast medium - the image shows a large hematoma in the temporo-parietal area on the right, which was caused by the rupture of the AVM.

File history

Click on a date/time to view the file as it appeared at that time.

	Date/Time	Thumbnail	Dimensions	User	Comment
current	14:42, 8 May 2022		630 × 630 (36 KB)	Tereza Bergendyová (talk contribs)	

You cannot overwrite this file.

File usage

The following page uses this file:

- Arteriovenous malformations