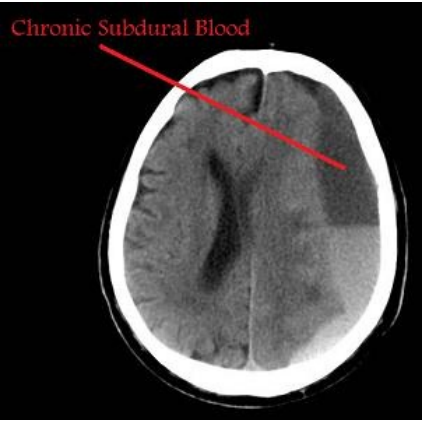


# File:CSDH.jpg



No higher resolution available.

CSDH.jpg (302 × 299 pixels, file size: 13 KB, MIME type: image/jpeg)

 [Open in Media Viewer](#)



## Summary

Please choose  
a more precise name for your image.

|description = CT of chronic subdural hematoma |author =Leeds Neurosurgery

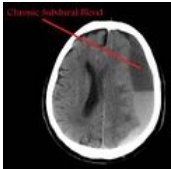
|source = http://www.leedsneurosurgery.com/patients/subdural/chronic/ |date = 07/08/2022 }}

## Licensing

Public domain

## File history

Click on a date/time to view the file as it appeared at that time.

	Date/Time	Thumbnail	Dimensions	User	Comment
current	12:31, 7 August 2022		302 × 299 (13 KB)	Saronw (talk   contribs)	File:File.jpg  description = CT of chronic subdural hematoma  author =Leeds Neurosurgery  source = http://www.leedsneurosurgery.com/patients/subdural/chronic/  date = 07/08/2022 }}

You cannot overwrite this file.

## File usage

The following page uses this file:

- Craniocerebral trauma