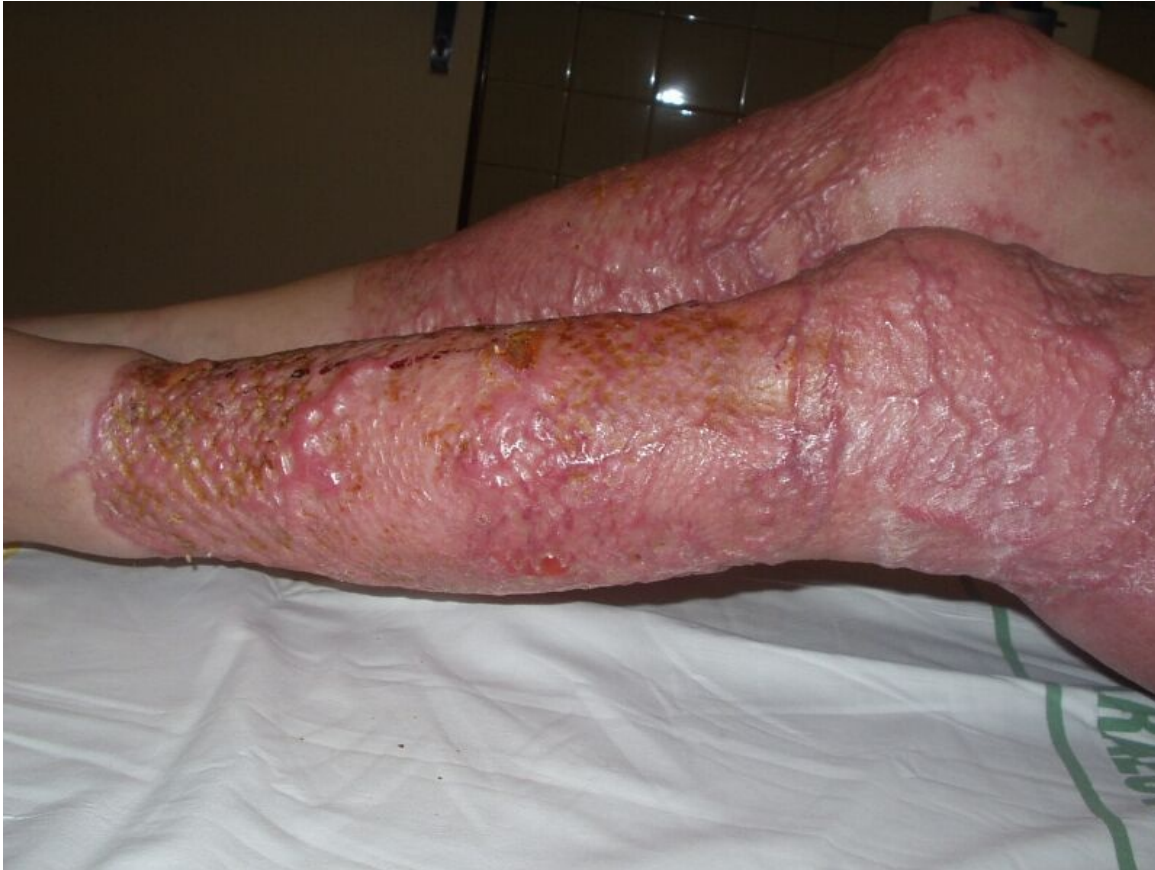

# File:Avulsion LL edema.jpg



Size of this preview: 800 × 600 pixels.

Original file (1,600 × 1,200 pixels, file size: 457 KB, MIME type: image/jpeg)

 **Open in Media Viewer** 

## Summary

### Description

Swelling of the lower limbs one year after avulsion

### Author

MUDr. Josef Bláha

### Source


[https://www.wikiskripta.eu/index.php?curid=28912#/media/Soubor:Avulze\\_DK\\_otoky.jpg](https://www.wikiskripta.eu/index.php?curid=28912#/media/Soubor:Avulze_DK_otoky.jpg)

### Date

16.12.2022

## File history

Click on a date/time to view the file as it appeared at that time.

	Date/Time	Thumbnail	Dimensions	User	Comment
current	<b>20:07, 16 December 2022</b>		1,600 × 1,200 (457 KB)	Terezaj (talk   contribs)	{ {File  description = Swelling of the lower limbs one year after avulsion  author = MUDr. Josef Bláha  source = <a href="https://www.wikiskripta.eu/index.php?curid=28912#/media/Soubor:Avulze_DK_otoky.jpg">https://www.wikiskripta.eu/index.php?curid=28912#/media/Soubor:Avulze_DK_otoky.jpg</a>  date = 16.12.2022 } }

You cannot overwrite this file.

## File usage

The following page uses this file:

- Fascial excision

## Metadata

This file contains additional information, probably added from the digital camera or scanner used to create or digitize it.

If the file has been modified from its original state, some details may not fully reflect the modified file.

Image title	OLYMPUS DIGITAL CAMERA
Camera manufacturer	OLYMPUS OPTICAL CO.,LTD
Camera model	C2Z,D520Z,C220Z
Exposure time	1/30 sec (0.033333333333333)
F Number	f/8
ISO speed rating	80
Date and time of data generation	Unknown date
Lens focal length	5 mm