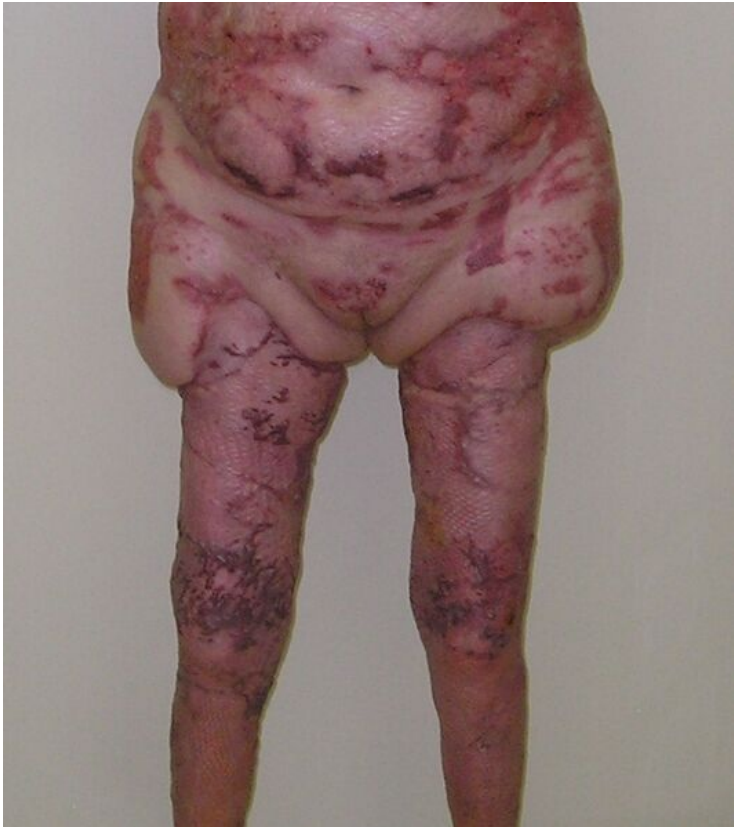

File:Avulsion LL consequences.jpg



Size of this preview: 531 × 599 pixels.

Original file (781 × 881 pixels, file size: 368 KB, MIME type: image/jpeg)

 [Open in Media Viewer](#) 

Summary

Description
Significant permanent consequences one year after avulsion in an obese patient


Author
MUDr. Josef Bláha

Source
https://www.wikiskripta.eu/w/Soubor:Avulze_DK_nasledky.jpg

Date
16.12.2022

File history

Click on a date/time to view the file as it appeared at that time.

	Date/Time	Thumbnail	Dimensions	User	Comment
current	20:09, 16 December 2022		781 × 881 (368 KB)	Terezaj (talk contribs)	{{File description = Significant permanent consequences one year after avulsion in an obese patient author = MUDr. Josef Bláha source = https://www.wikiskripta.eu/w/Soubor:Avulze_DK_nasledky.jpg date = 16.12.2022 }}

You cannot overwrite this file.

File usage

The following page uses this file:

- Fascial excision

Metadata

This file contains additional information, probably added from the digital camera or scanner used to create or digitize it.
If the file has been modified from its original state, some details may not fully reflect the modified file.

Image title	OLYMPUS DIGITAL CAMERA
Camera manufacturer	OLYMPUS CORPORATION
Camera model	X300,D565Z,C450Z
Exposure time	1/30 sec (0.033333333333333)
F Number	f/3.1
ISO speed rating	100
Date and time of data generation	Unknown date
Lens focal length	5.8 mm