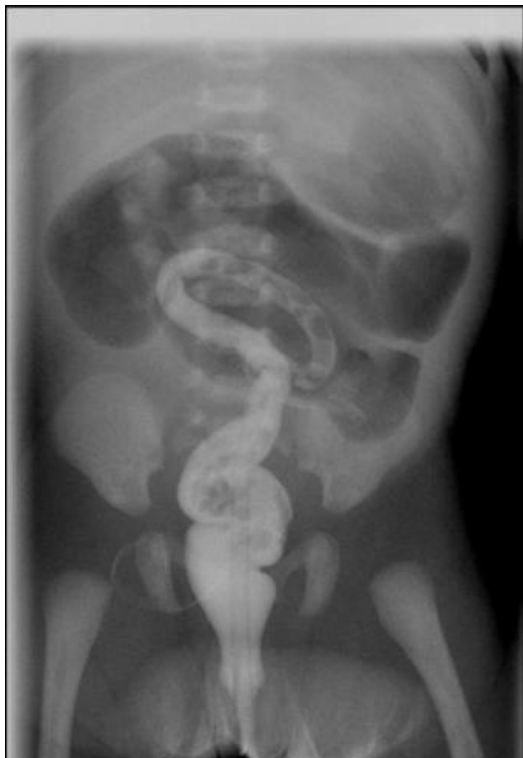

# File:Atrezie jejuna IV. typ 2. snimek.JPG



No higher resolution available.

Atrezie\_jejuna\_IV.\_typ\_2.\_snimek.JPG (338 × 491 pixels, file size: 15 KB, MIME type: image/jpeg)

## Summary

### Description

Irrigography in a patient with type IV jejunal atresia

### Author

FNM KZM

### Source


FNM KZM

### Date

2016

## File history

Click on a date/time to view the file as it appeared at that time.

	Date/Time	Thumbnail	Dimensions	User	Comment
current	<b>02:34, 18 January 2022</b>		338 × 491 (15 KB)	MartinRuzicka (talk   contribs)	{ {File  description = Irrigography in a patient with type IV jejunal atresia  author = FNM KZM  source = FNM KZM  date = 2016 } }

You cannot overwrite this file.

## File usage

The following page uses this file:

- Congenital defects of the gastrointestinal tract